

Personal pdf file for
F. del Piñal, F. Tandioy-Delgado

With compliments of Georg Thieme Verlag

www.thieme.de

(Dry) Arthroscopic Partial Wrist Arthrodesis: Tips and Tricks

DOI 10.1055/s-0034-1387707

Handchir Mikrochir Plast Chir 2014; 46: 300–306

For personal use only.
No commercial use, no depositing in repositories.

Publisher and Copyright

© 2014 by
Georg Thieme Verlag KG
Rüdigerstraße 14
70469 Stuttgart
ISSN 0722-1819

Reprint with the
permission by
the publisher only



(Dry) Arthroscopic Partial Wrist Arthrodesis: Tips and Tricks

(Trockene) arthroskopische Handgelenksteilversteifung: Tipps und Tricks

Authors

F. del Piñal¹, F. Tandioy-Delgado²

Affiliations

¹ Instituto de Cirugía Plástica y de la Mano, Private practice and Hospital Mutua Montanesa, Santander, Spain

² Formerly Fellow, presently Clínica las Américas, Hand Surgery, Medellín, Antioquia, Colombia

Key words

- arthroscopy
- arthrodesis
- dry arthroscopy
- partial wrist arthrodesis

Schlüsselwörter

- Arthroskopie
- Arthrodes
- „trockene“ Arthroskopie
- Handwurzelsteilversteifung

Abstract

One of the options for performing a partial wrist arthrodesis is the arthroscopic technique. As a first advantage arthroscopy allows us to directly assess the state of the articular surface of the carpal bones and define the best surgical option during the salvage operation. Furthermore, it allows performance of the procedure with minimal ligament damage and minimal interference with the blood supply of the carpals. These will (presumably) entail less capsular scarring and more rapid healing. Lastly, there is cosmetic benefit by reducing the amount of external scarring. The procedure has a steep learning curve even for accomplished arthroscopists but can be performed in a competitive manner to the open procedure if the dry technique is used. The aim of this paper is to present the technical details, tricks and tips to make the procedure accessible to all hand specialists with an arthroscopic interest. As it is paramount that the surgeon is acquainted with the “dry” technique, some technical details about it will also be presented.

Zusammenfassung

Teilversteifungen des Handgelenkes können arthroskopisch durchgeführt werden. Dabei ist es mittels der Arthroskopie möglich, die Knorpelsituation der Handwurzelknochen zu beurteilen und hierauf basierend noch während der Rettungsoperation zu entscheiden, was der bestsinnvollste Eingriff ist. Darüber hinaus minimiert der arthroskopische Eingriff Schäden am Bandapparat und Beeinträchtigungen der Blutversorgung der Karpalia. Es steht zu vermuten, dass dies zu einer geringen Vernarbung der Gelenkkapsel und zugleich zu einer schnelleren Heilung führt. Auch ästhetisch ist die Verkleinerung des Hautschnittes von Vorteil. Allerdings haben selbst erfahrene Arthroskopeure eine steile Lernkurve mit dem Verfahren, auch wenn das arthroskopische Vorgehen sehr wohl mit der offenen Operation vergleichbar ist, sofern die Arthroskopie „trocken“ erfolgt. Ziel der vorliegenden Arbeit ist es, technische Details darzustellen und Tricks und Tipps zu geben, um jedem Handchirurgen mit Interesse an der Arthroskopie das Verfahren nahezubringen. Da es wichtig ist, dass der Handchirurg mit der „trockenen“ Arthroskopie vertraut ist, werden auch hierzu einige technische Details präsentiert.

received 14.07.2014
accepted 19.07.2014

Bibliography

DOI <http://dx.doi.org/10.1055/s-0034-1387707>
Handchir Mikrochir Plast Chir
2014; 46: 300–306
© Georg Thieme Verlag KG
Stuttgart · New York
ISSN 0722-1819

Correspondence

Francisco del Piñal

Instituto de Cirugía Plástica y de la Mano
Private practice
Hospital Mutua Montanesa
Cirugía Plástica
Paseo de Pereda 20-1
39004 Santander
Spain
drpinal@drpinal.com

Introduction

Partial arthrodeses are well-accepted procedures when dealing with unsalvageable carpal damage in the wrist. Although these procedures are mostly performed in an open manner, Ho, in a pioneering work, opened up the possibility of carrying these procedures arthroscopically [1]. Skeptics may regard this as another arthroscopic filigree, however, the method is sound and has several advantages. Perhaps the most obvious is an aesthetic benefit, but in our view it is the least important benefit. Under arthroscopy, minimal

damage to the ligaments and capsule is produced which, in turn, will preserve the blood supply to the carpals and produce less scarring. Logically this will result in more rapid healing and a better range of motion. Furthermore, as the posterior interosseous nerve is preserved, the proprioception of the joint is maintained [2], perhaps resulting in less arthritic changes and better healing [3]. Additionally, during the initial steps of the procedure a precise evaluation of the damage – and the preserved cartilage surfaces – prior to starting the procedure is done with minimal invasiveness. Last but not least, an obvious

cosmetic benefit is also associated with any minimally invasive procedure.

Although the idea of minimizing surgical insult to the wrist is appealing, the technique as presented by Ho was difficult to implement: First an operation lasting longer than 3 hours was required, and second, the swelling, due to fluid extravasation, made the technique more difficult in some parts of the operation. We have championed the “dry” arthroscopic technique [4,5], which is basically similar to the classical “wet” technique. However, in the dry technique no water is used to maintain the optic cavity but the traction itself. In the case of complex operations, such as a distal radius fractures [6,7], partial wrist arthrodesis or any semiopen operation, the dry technique allows the operation to be performed without fluid extravasation or constant loss of vision: water tightness is not an issue. In the case of arthroscopic arthrodesis the technique is greatly facilitated by not using constantly fluid. Firstly the bony landmarks are not blurred by the extravasated fluid (● Fig. 1), greatly facilitating the introduction of the guidewires. Furthermore, it allows removal of the bones with a rongeur rather than with a burr, speeding up the procedure to the point that some of the complex arthroscopic operations can be performed in a competitive “less than a tourniquet time” [8].

Indications

The surgeon should warn the patient that sometimes the type of procedure may be modified intraoperatively after evaluating the cartilage status of each of the joints. Otherwise, the indications for arthroscopic partial arthrodesis are the same as for open procedures, and are beyond the scope of this article.

Contraindications

Needless to say, the arthroscopic assisted arthrodesis shares the same contraindications as the open counterpart, among the most prominent: generalized osteoarthritis and acute infection.

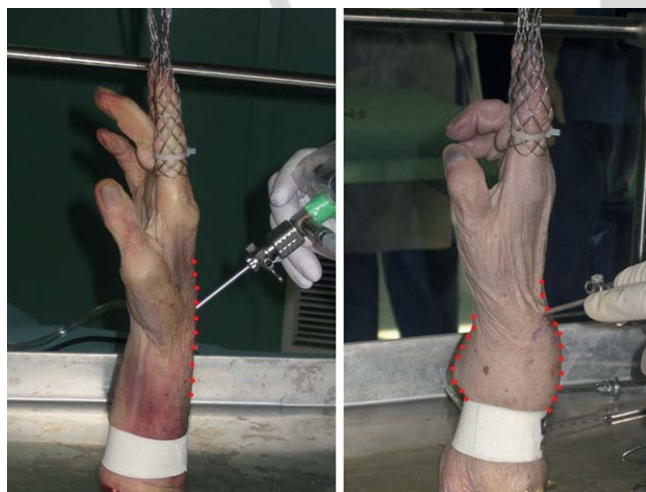

Fig. 1 The deformity of the wrist due to fluid extravasation after 1 h of wet arthroscopy (right) as compared to the left which was operated for the same amount of time but under the dry technique (Pictures taken during a teaching course with cadavers in Strasbourg. Both were operated by students simultaneously in different working posts). (Copyright Dr. Piñal, 2010).

Chronic smoking may affect the rate of union of the arthrodesis, but we have not excluded any patient for such a reason.

We should warn that the “dry” technique is contraindicated when using vaporizers, lasers, etc, as the heat generated will not dissipate, risking widespread cartilage damage. The problem is solved easily, however, by swapping to the “wet” technique during the specific moment those types of instruments are being used. Once the “vaporizer step” is terminated, the saline is disconnected and air allowed to flow in the joint. The remaining water is sucked out with the synoviotome and the procedure continues in the “dry” manner (see below).

One concern that many surgeons have about the dry arthroscopy is the possibility of burning inside the joint by the tip of the scope. This has never occurred in our experience, as the tip of the scope never warms up to that point. We should warn the reader, however, that we have experienced minor contact burns at the portals and the dorsal skin, by the synoviotome and burr. The rotating mechanism of these instruments heats up, as a result of friction, when used for very long periods of time. This is easily overcome by flushing the joint with saline that will cool down the synoviotome, and also will improve vision, as we normally do during the operation (see below).

Surgical Technique

As it is paramount that the surgeon be familiar with the dry technique, a brief description of the technique is first presented.

Surgical technique of dry arthroscopy

The “dry” arthroscopy technique is similar to a standard wrist arthroscopy (“wet”), except for the fact that water is not used to maintain the optic cavity. The main shortcoming comes from the fact that if one is not able to get rid of the blood and splashes that obscure vision in an expeditious manner, surgery will become difficult and one will give up the dry technique.

Intuitively, one would think that removing the scope and wiping off the lens with a wet sponge is a good way of having clear vision. Although effective, this maneuver is time consuming and, in a fracture or other complex procedures, there may be so much blood or debris that the maneuver may need to be repeated an exasperating number of times. Based on our experience we can recommend the following tips that are critical for a smooth procedure [4,5]. Firstly, the valve of the sheath of the scope should be kept open at all times to allow the air to circulate freely inside the joint. Otherwise, either the suction of the shaver will not function properly, or the capsule will collapse inwards due to the power of the suction, resulting in blocked vision. This is critical and cannot be overemphasized (● Fig. 2).

Secondly, suction is necessary to clear the field but, paradoxically, suction might also blur the vision by stirring up the contents of the joint (debris, blood or remaining saline) that may stick to the tip of the scope. It is critical therefore, to open the suction of the shaver or burr only when there is the need to aspirate something. Suction power should be locked when not needed. To sum up, the valve of the sheath of the scope should be open at all times, but suction power should only be working when needed.

Thirdly, when a clear field is needed, so as to see a gap or a step-off, we recommend connecting a syringe with 5–10 mL of saline to the side valve of the scope and then aspirate it with the synoviotome, in order to get rid of blood and debris. Pressure on the

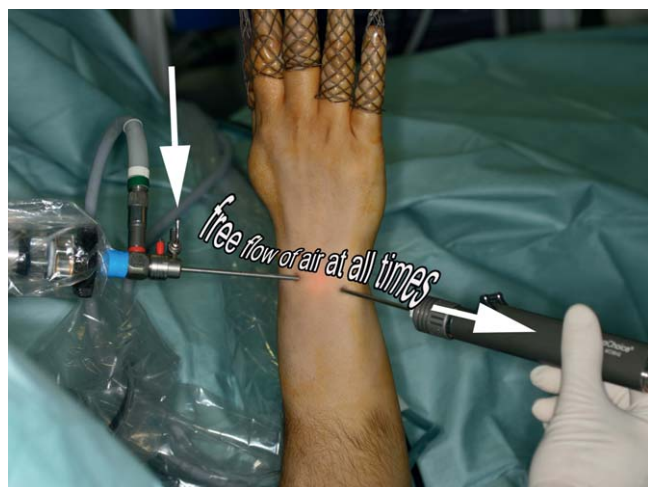


Fig. 2 The valve of the scope should be open at all times so as to allow air to circulate freely. ([7], Copyright by Springer-Verlag, 2009).

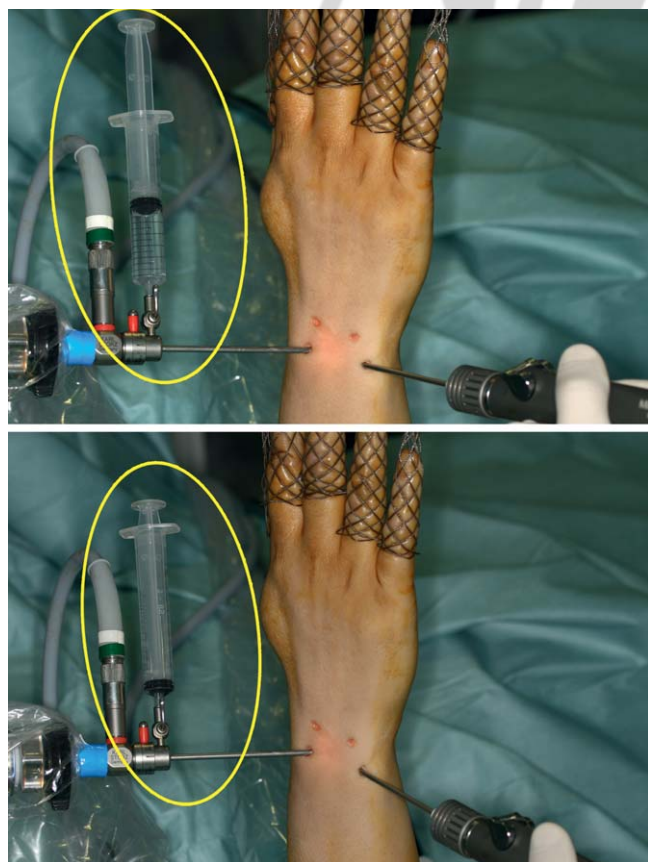


Fig. 3 Method used to wash out the joint and clear it of blood. Notice that the negative pressure exerted by the shaver is sufficient to aspirate the saline without extravasation of water. ([7] Copyright by Springer-Verlag, 2009).

plunger of the syringe is unnecessary, as the negative pressure exerted by the shaver will suck the saline into the joint, thus preventing any extravasation (• Fig. 3). Once all the water has been aspirated, the syringe is removed, and again the suction power of the shaver is enough to dry out the joint sufficiently, thus allowing the surgeon to work. This maneuver should be repeated as necessary throughout the procedure, as it is much

quicker than struggling with blood in the joint, or trying to dry it out with the patties.

A significant waste of time occurs when the synoviotome, burr or any other instruments are connected to a suction machine. When this happens the operation has to be stopped in order to dismount and irrigate the synoviotome to dislodge the debris. This is to be avoided at all costs by clearing the tubing with periodic saline aspiration from an external basin by the OR nurse, or by the surgeon through joint irrigation. Joint flushing should also be done in a systematic fashion in some procedures, such as intercarpal arthrodesis or arthroscopic proximal carpectomy, in which prolonged use of the synoviotomes and burrs may cause heating of the instrument itself causing local burns.

Fourthly, one must understand that at most times vision will never be completely clear but still sufficient to safely accomplish the goals of the procedure. Having a completely dried field except for specific times during the procedure is unnecessary and wastes valuable time, and we rely more on the irrigation-suction.

Surgical technique of the arthroscopic 4 corner arthrodesis (A-4CA)

With some variations (depending on the area that the surgeon has to fuse) the technique is very similar. We firstly describe in detail the technique for the A-4CA, this being the most complicated procedure (technically speaking), and the one in which we have accumulated more clinical experience [8].

Under axillary block, the arm is exsanguinated and a tourniquet applied. The hand is suspended from a bow, the fingers pointing to the ceiling, with a custom made system that allows easy connection and disconnection from the bow without losing sterility [9]. Counter traction is usually 10–12 kg, but can be more in tight wrists. No adverse effects have been noticed perhaps because the traction is evenly distributed to all fingers. This system has the advantage of its availability and price (8 euros each karabiner). Furthermore, it is very easy to fasten and unfasten for fluoroscopy checking. We use the 2.7 mm/30° angle scope for most of the cases. Seldom, in tight wrists, do we use a 1.9 mm/30° angle, as the field of vision is reduced.

Creation of a (large) scapholunate (S-L) portal: The procedure commences by creating the portals, which are easily made ulnarly (6R and UMC), but in advanced SLAC or SNAC wrists not so easily radially. This is due to architectural derangement of the carpus and often scarring from previous surgery. Our preference is to create a large (1.5 cm) transverse “scapholunate portal” (midway between 3–4 and RMC) corresponding to the location of the scapholunate gap or the scaphoid non-union (• Fig. 4). From there, work can be performed in both radiocarpal and mid-carpal directions.

Scaphoid excision with rongeurs: The previous description of A-4CA and A-PRC [1, 10] resected the bone with a burr; it is time consuming and the scaphoid cannot be reused as a bone graft. Conversely, using pituitary rongeurs, the scaphoid can be excised expeditiously and the cancellous bone graft reused later (• Fig. 5, 6).

Midcarpal joint preparation: The cartilage and subchondral bone at the site of the 4CA are removed with a burr. A 3.0-mm pineapple burr is preferred because it tends not to get caught on bone and produces a more even surface of bone as opposed to pits created by the round burr. During burring, the suction of the instrument is maintained in the off position. Otherwise, the suction stirs up the contents of the joint and obscures the visual

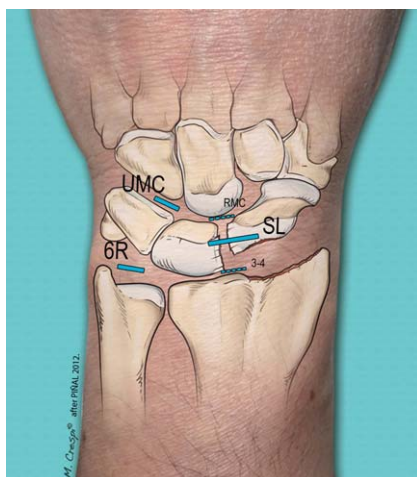


Fig. 4 The SL portal is located midway between the 3–4 and radial midcarpal portals (SL: scapholunate portal; RMC: radial midcarpal; UMC: ulnar midcarpal) [8]. Copyright Dr. Piñal, 2012.

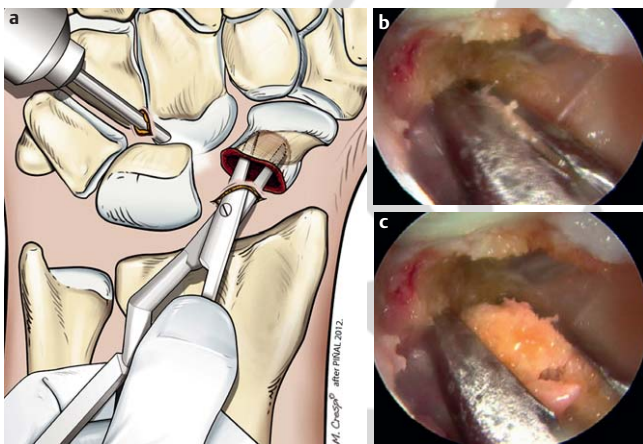


Fig. 5 The process of scaphoid resection with a rongeur. **a** With the scope in UMC the surgeon scoops out the middle third of the scaphoid with the rongeur. **b** and **c** corresponding arthroscopic views.

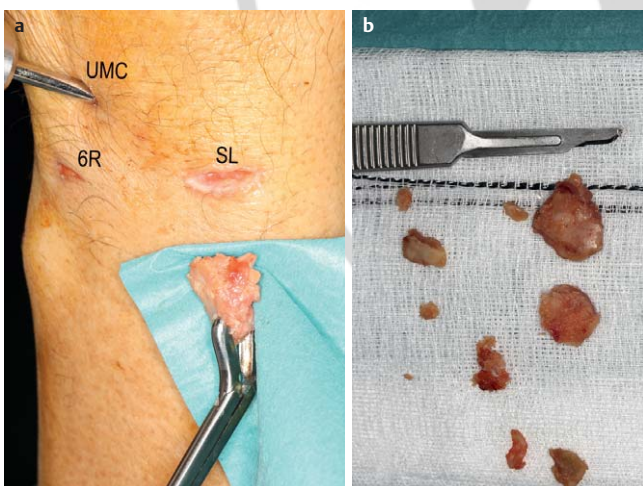


Fig. 6 **a** A large piece of a scaphoid osteophyte is being extracted from the dorsal aspect of the capsule with the 90° angled rongeur. **b** Notice the great number of small bone fragments and loose bodies that had to be removed from the wrist capsule in this case of an advanced SNAC wrist (SL: scapholunate portal; UMC: ulnar midcarpal portal; 6R portal). [8], Copyright Dr. Piñal, 2012.

field. To remove debris and prevent the burr from clogging, aliquots of 5–10 mL saline are flushed through the scopes side valve with a syringe. The suction is turned on at that specific time, and once the debris is removed the suction is again turned off.

Lunate reduction: After the joint surfaces are appropriately prepared, the hand is removed from the traction device to reduce the lunate. To correct the extended and ulnar translated lunate, the wrist is maximally flexed and radially translated. The lunate reduction is maintained with a K-wire (1.25 mm), which is inserted about 2 cm proximal to the 4–5 portal and directed slightly radially.

Bone grafting: With the lunate reduced, the hand is again placed on traction to allow for the placement of a bone graft under arthroscopic guidance. The cavity during traction is large, but we focus on filling the anterior aspects of the lunocapitate and triquetrohamate joints as well as the most distal aspect of the lunotriquetral joint only. For the other surfaces, bone graft is not needed because cancellous bone will contact cancellous bone once the joint is reduced. After trying several devices and methods, the technique we now employ to deliver the bone graft inside the joint is a 3.5 mm (or even 4.5 mm) drill guide (● Fig. 7). The cancellous bone is loaded into the guide outside the wrist, and the guide is then placed into the joint through the SL portal. A shoulder probe, acting as a plunger, then delivers the bone into the joint, and the bone graft is manipulated into the appropriate position with a small Freer elevator or the probe itself (● Fig. 8).

Midcarpal reduction and fixation: After the bone graft is placed, the hand is taken off traction, the midcarpal joint is reduced (translocating the capitate ulnarly), and the guidewires for the cannulated screws are inserted. This critical step, one of the trickiest parts of the operation, is greatly facilitated by the

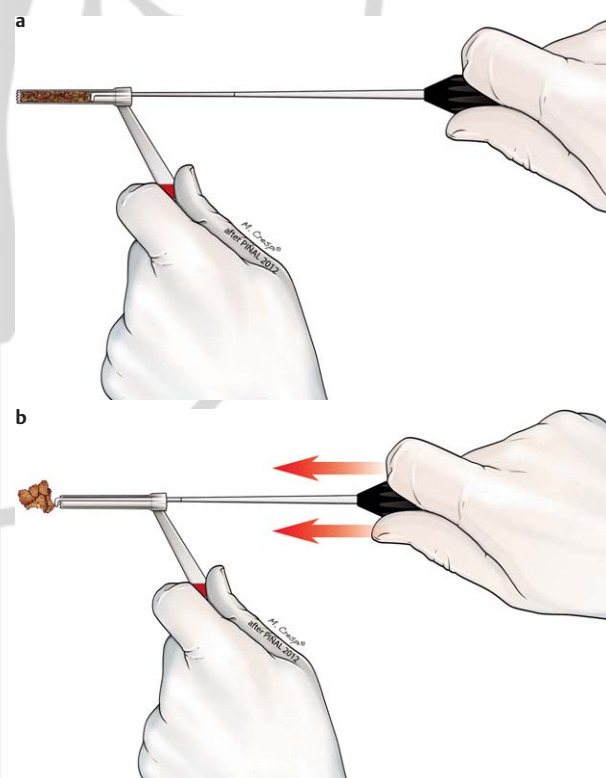


Fig. 7 Schematic representation of the bone grafting technique (Copyright Dr. Piñal, 2012).

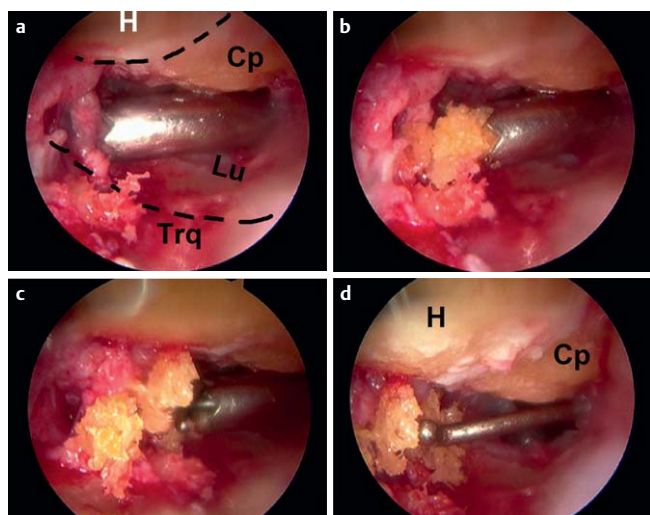


Fig. 8 The process of introducing the bone graft into the midcarpal space is shown. **a** A 3.5 mm drill guide, fully loaded with cancellous bone graft introduced from SL portal is facing the palmar aspect of the lunate and triquetrum (Lu: lunate; Trq: triquetrum). **b** The plunger (the shoulder hook in this case) is starting to push the bone graft to the joint space. **c** All the bone graft has been delivered in to the joint. **d** The shoulder probe or a small Freer elevator is used to compress the bone against the palmar ligaments (H: hamate; Cp: capitate). [8], Copyright Dr. Piñal, 2012.

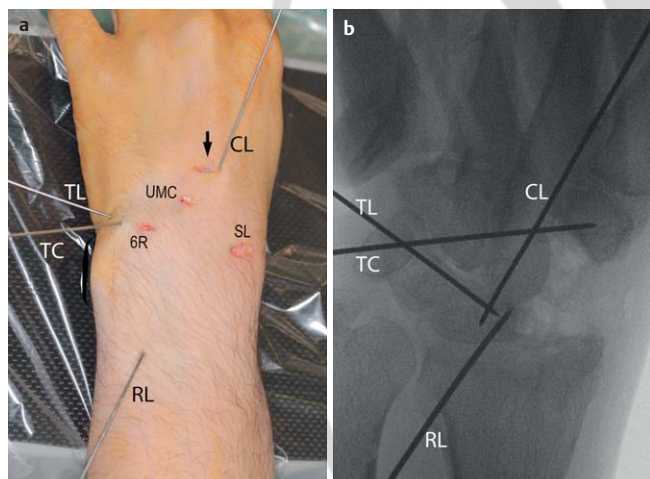


Fig. 9 View of the hand **a** and corresponding fluoroscopic view **b** at the end of the insertion of the guidewires. Notice that the hand is not swollen even at this late stage of the operation (TC: triquetro-capitate; TL: triquetro-lunate; RL: radio-lunate; CL: capito-lunate; SL: scapholunate portal; UMC: ulnar midcarpal portal. Arrow points to the incision needed for the insertion of the capitollunate screw). [8], Copyright Dr. Piñal, 2012.

dry arthroscopic technique: the bony anatomy is easily palpated because the swelling that results from the classic wet technique is avoided (• Fig. 9).

The guidewires are placed in such a fashion as to maximize purchase and avoid screw collision: The capitollunate screw is directed from the dorsal distal aspect of the capitate to the palmar proximal aspect of the lunate, the triquetrolunate screw is directed from the palmar triquetrum to the dorsal lunate, and the triquetrocapitate screw is directed from the dorsal distal triquetrum to the palmar distal capitate. This technique avoids the problem of one screw interfering with placement of the next (• Fig. 10).

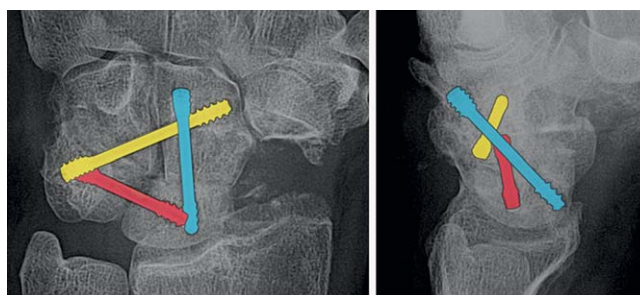


Fig. 10 Ideally the screws should be placed to avoid collision and provide maximal purchase as explained in the text. [8], Copyright Dr. Piñal, 2012.

A small transverse incision is made at the base of the long finger metacarpal for guidewire insertion and later drilling of the capitate. This allows for protection of the extensor tendon of the third finger. The surgeon's hand must be oriented nearly parallel to the patient's wrist during insertion of this guidewire; otherwise, the lunate is missed. Presently, we favor another small transverse incision over the triquetrum to insert the ulnar screws, as we fear that the dorsal branch of the ulnar nerve, the extensor carpi ulnaris and the extensor digiti minimi may be at risk if done percutaneously as we used to recommend previously [8].

Correct placement of the guidewires is confirmed on fluoroscopy. Screws of appropriate length and size (presently we use 3-mm (or even 2.5-mm) titanium AutoFIX™ [Small Bone Innovations, New York, NY]) are inserted after predrilling the port of entrance only. The radiolunate Kirschner wire is removed and a final fluoroscopic check is performed. Although the carpal height is restored by repositioning the capitate on the lunate, the radial styloid may continue to abut the carpus. In this case, the styloid should be resected. This actually takes little time to complete with the rongeur introduced through the SL portal. Care should be taken to preserve the RSC ligament origins intact on the radius. Finally, the SL portal incision is closed with intradermal sutures and the other portals are dressed with non-adherent gauze. Protected range of motion is commenced at about 2–3 weeks.

To date, the senior author has performed 17 cases of dry A-4CA (• Fig. 11). We have been very satisfied with the early results, and only have had problems with union in one case where immediate range of motion was permitted. Now we stick to the original protocol and only allow mobilization when there is no local tenderness on palpation at the fusion mass, and never before the 3rd week.

Other partial arthrodesis procedures

With minimal variations over the presented technique it is possible to carry out other (perhaps any) forms of partial arthrodesis. Due to the frequent involvement of the radiocarpal joint after unsalvageable malunions, the arthroscopic radioscapulolunate arthrodesis (A-RSLA) is also a common procedure. The operation is more difficult than the A-4CA as the surgeon has first of all to remove colossal amounts of fibrous tissue and debris in the radiocarpal joint to be able to create a working space. Not only the scarring but also the malunited fragments complicate the first part of the operation. Triangulation may take some patience and at times more traction (up to 15 kg) may be helpful. The surgeon should take into account that undue force

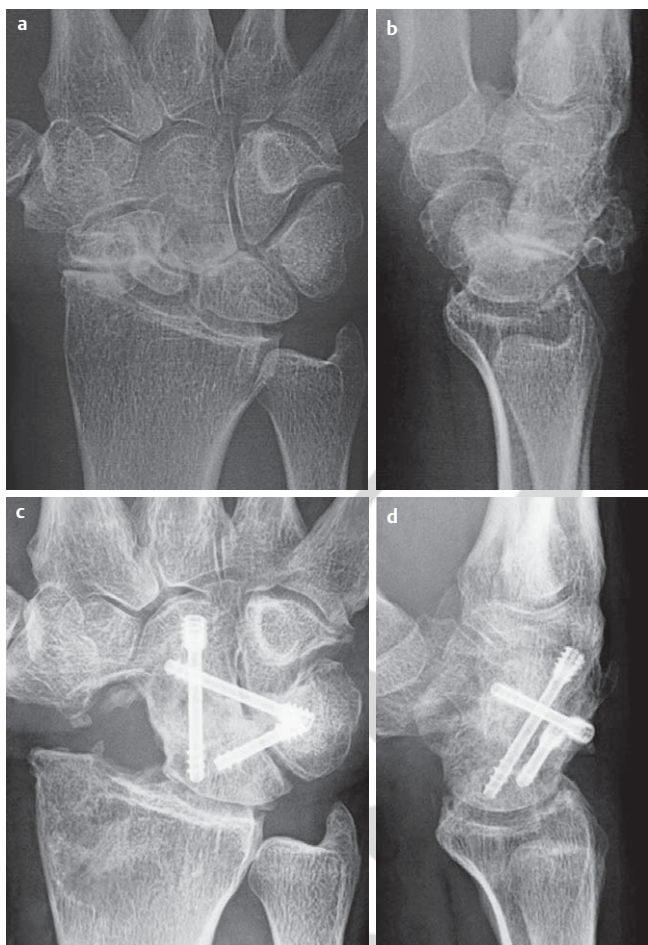

Fig. 11 SNAC III. **a, b** Preoperative, **c, d** postoperative plain X-rays. [8], Copyright Dr. Piñal, 2012.

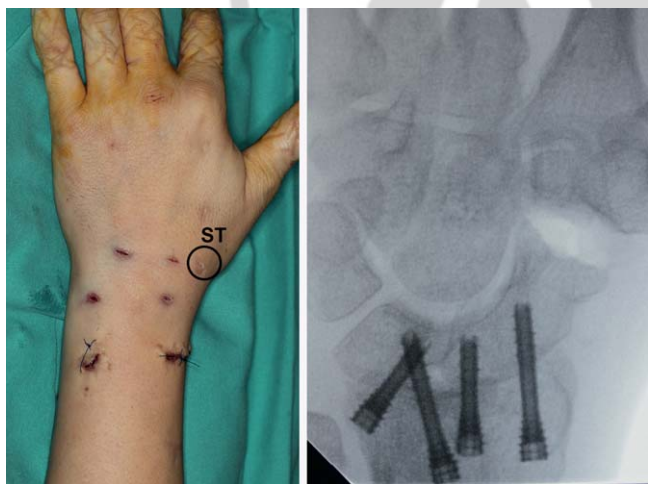

Fig. 12 **a** Notice minimal swelling at the end of the operation in a case of an RSL arthrodesis, resection of the distal pole of the scaphoid was also carried out through the ST portal. Cannulated screws were inserted through the proximal incisions (arrows). **b** Corresponding fluoroscopic view. Copyright Dr. Piñal, 2013.

and rough maneuvers may put at risk the scope itself. A good trick is to use the sheath of the scope with the trocar inside to swipe inside the joint bluntly to break all possible adhesions and create the working space. In this manner the “hard” part of

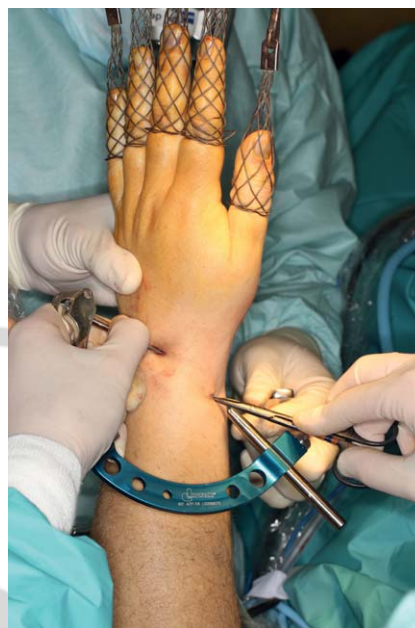

Fig. 13 One of the commercially available arthroscopic guides (Dyonics®) is being set in place at the time of an RSL arthrodesis. The guide is a bit cumbersome for the purpose but helps to place some of the difficult guidewires in the exact spot intra-articularly. Copyright Dr. Piñal, 2014.

the work is done without the scope in the sheath. We recommend starting by checking the cartilage of the midcarpal space by the midcarpal portals. Once this is done, one should stay away from the midcarpal joint to avoid any iatrogenic damage in the (from now on) only joint of the wrist. There is now controversy as to the need to remove the distal pole of the scaphoid in RSLA [11]. We only do so when the passive range of motion of the wrist is limited intraoperatively after the radiocarpal joint has been stabilized. To excise the distal pole an accessory palmar or the ST portal is needed (► Fig. 12). Bone graft is taken from the olecranon only in cases where there are major bone defects, as the cancellous mass in contact at the end of the operation is considerable.

Discussion

So far we have presented the favorable aspects of the arthroscopic arthrodesis. On the drawback side of the arthrodesis performed arthroscopically is the longer operative time required compared to the open procedures. An A-4CF can reliably be performed in less than 2 h, but an A-RSL rarely is attainable in a tourniquet time [8]. Interestingly the bulk of the time is spent introducing the guidewires for the cannulated screws, as only palpation and the surgeon's spatial orientation are used. We are at this time exploring different arthroscopic guides to speed up the procedure, but the available ones are bulky and difficult to fit into a wrist. Newer prototypes surely will be available soon (► Fig. 13).

We should stress also that the technique is demanding and in the highest rank of difficulty in the arthroscopic ladder. Nevertheless, with appropriate planning any fixation can be performed arthroscopically (► Fig. 14). On the other hand, with more experience and implementation of the fixation techniques, reduction of the operating time is foreseeable. Notwithstanding those difficulties, the reader should take into account that the possibility of achieving complex fixations through minimally invasive surgery represents the future of wrist surgery and the direction in which we should head.

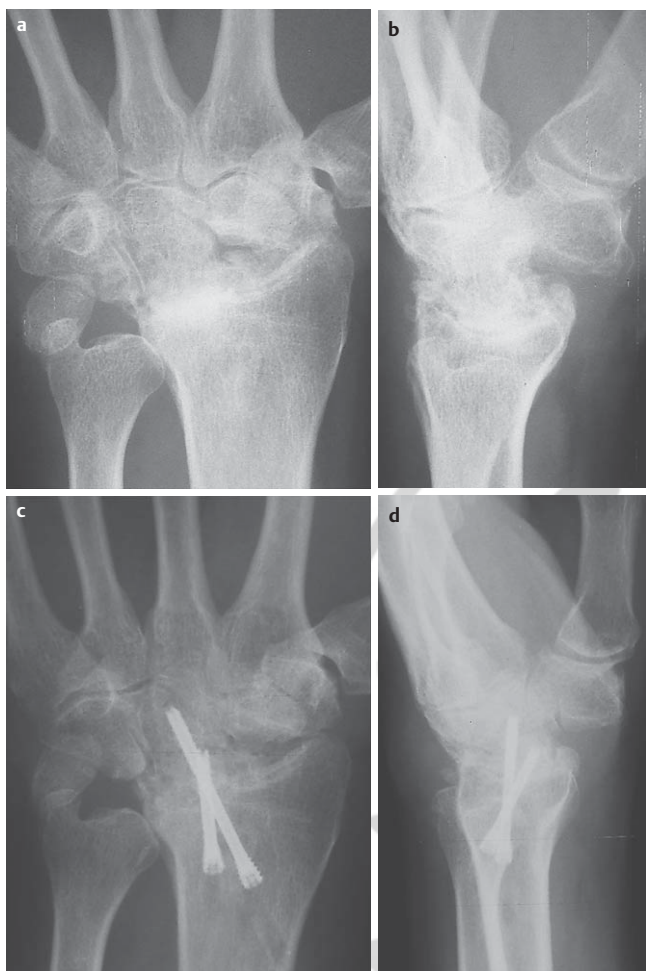

Fig. 14 a, b Failed carpectomy. c, d The radio-capitate joint has been fused arthroscopically. Bone graft from the olecranon was added to increase the fusion mass. (Copyright Dr. Piñal, 2014).

Conclusions

Partial wrist arthrodesis can be performed safely and successfully under arthroscopy. However, to do so in an efficient and convenient way the surgeon must use the dry technique. Despite the fact that one typically resists modifying a technique with which one is familiar, the authors consider that the transition to the dry technique is worthwhile because of its great advantages and merits. Although the advantages of this method are minimal when carrying out the simple arthroscopic procedures, the dry technique simplifies the complex arthroscopic operations, (such as the ones discussed in this article) enormously. Therefore, sooner or later, even the most reluctant wet arthroscopist will have to change to the dry technique to get the most that arthroscopy of the wrist offers. Also, any accomplished wrist arthroscopist will have minimal difficulty switching between wet and dry techniques.

Again we must emphasize that the procedures described in this article have a steep learning curve even for skilled arthroscopists and require the surgeon to have accurate spatial orientation at the time of the placement of guidewires. The lack of tissue infiltration greatly facilitates the latter, as the bony references remain unaffected.

Conflict of interest: None



Francisco del Piñal

- Born in Santander, Spain. 1960.
- MD degree from University Complutense. Madrid. 1983.
- Dr Med degree from University Complutense. Madrid. 1989
- Plastic Surgery training in Hospital Universitario 12 de Octubre. Madrid 1983–1988.
- Fellow in Microsurgery with Ian Taylor (Melbourne, Australia). 1989.
- Fellow in Hand Surgery in Kleinert Group (Louisville, KY, USA) 1990.
- Editor. Revista Iberoamericana de Cirugía de la Mano. 2004–2007.
- Associate Editor. The Journal of Hand Surgery (European Volume); 2007–2009.
- President: The European Wrist Arthroscopy Society (2008–2010).
- Secretary General: The European Wrist Arthroscopy Society 2011–2014.
- Editor. The Journal of Hand Surgery European volume. 2012–2013.
- Editor in chief of: Arthroscopic management of distal radius fractures (Springer 2010) and Arthroscopic management of ulnar pain (Springer, 2012).
- Publications: Papers and chapters more than 100 and 400 presentations.
- Keynote speaker: Australian, Argentinian, South African, Belgian, Italian, Japanese, Indian, Polish, Dutch, Hong-Kongnese ... Hand and Plastic surgery societies.
- Presently: Head of the Institute for Hand-Wrist and Plastic Surgery. Private Practice and Hospital Mutua Montañesa. Santander. Spain.
- Main interests: Wrist, arthroscopy, microsurgery, toe transfer for reconstruction of the mutilated hand.

References

- 1 Ho PC. Arthroscopic partial wrist fusion. *Tech Hand Up Extrem Surg* 2008; 12: 242–265
- 2 Hagert E, Ferreres A, Garcia-Elias M. Nerve-sparing dorsal and volar approaches to the radiocarpal joint. *J Hand Surg* 2010; 35A: 1070–1074
- 3 Ivie TJ. Denervation impairs healing of the rabbit medial collateral ligament. *J Orthop Res* 2002; 20: 990–995
- 4 Del Piñal F, García-Bernal FJ, Pisani D et al. Dry arthroscopy of the wrist: surgical technique. *J Hand Surg* 2007; 32A: 119–123
- 5 Del Piñal F. Dry arthroscopy and its applications. *Hand Clin* 2011; 27: 335–345
- 6 Del Piñal F. Treatment of explosion-type distal radius fractures. In del Piñal F, Mathoulin C, Luchetti C (eds.). *Arthroscopic Management of Distal Radius Fractures*. Springer Verlag; Berlin: 2010; 41–65
- 7 Del Piñal F. Technical tips for (dry) arthroscopic reduction and internal fixation of distal radius fractures. *J Hand Surg* 2011; 36A: 1694–1705
- 8 Del Piñal F, Klausmeyer M, Thams C et al. Early experience with (dry) arthroscopic 4-corner arthrodesis: from a 4-hour operation to a tour-niquet time. *J Hand Surg Am* 2012; 37: 2389–2399
- 9 Del Piñal F, García-Bernal FJ, Delgado J et al. Correction of malunited intra-articular distal radius fractures with an inside-out osteotomy technique. *J Hand Surg* 2006; 31A: 1029–1034
- 10 Weiss ND, Molina RA, Gwin S. Arthroscopic proximal row carpectomy. *J Hand Surg* 2011; 36A: 577–582
- 11 Mühldorfer-Fodor M, Ha HP, Hohendorff B et al. Results after radioscapulohumeral arthrodesis with or without resection of the distal scaphoid pole. *J Hand Surg Am* 2012; 37: 2233–2239