Arthroscopic Assisted Treatment of Combined Trapezium and Bennett Fracture-Dislocation

Fabio Andrés Tandioy-Delgado, MD, Lucian Lior Marcovici, MD,† Riccardo Luchetti, MD,‡ and Andrea Atzei, MD§*

Abstract: Trapezium fractures are unusual; however, they represent the third most frequent fracture of the carpal bones. As they usually follow a high-energy trauma, they are associated with distal radius, Bennett, or Rolando fractures in 80% of cases. Traditional treatment options include, closed reduction and percutaneous pinning, or open reduction and internal fixation. To minimize the additional surgical trauma, an arthroscopic technique has been developed for safe, minimally invasive management of complex injuries of the first carpo-metacarpal joint. Intra-articular dislocated fracture fragments are reduced under direct visualization and fixed through small incisions. Limiting additional surgical damage on the carpo-metacarpal joint ligaments, capsule, and other soft tissues around the fracture preserves the blood supply to fracture fragments and also the proprioceptive system, which is key for the dynamic stability of such a hypermobile joint. This report confirms that the procedure is feasible, and a complete functional recovery can be expected with reduced postoperative rehabilitation.

Key Words: wrist, arthroscopy, trapezium fracture, bennet fracture

(*Tech Hand Surg* 2022;00: 000–000)

The first carpo-metacarpal joint (CMC-1j) is essential for the movement and function of the thumb. Daily activities that involve grasping or holding can be greatly affected by an injury to this joint.

The trapezial and metacarpal surfaces are opposed in an inherently unstable joint, which is particularly at risk of fracture or dislocation following trauma that occurs with the outstretched hand, as in a fall or other defensive positions. Isolated trapezium fractures are unusual; they account for only 3 to 5% of all carpal fractures.[1–6] Nevertheless, they represent the third most frequent fracture of the carpal bones. These fractures are produced by

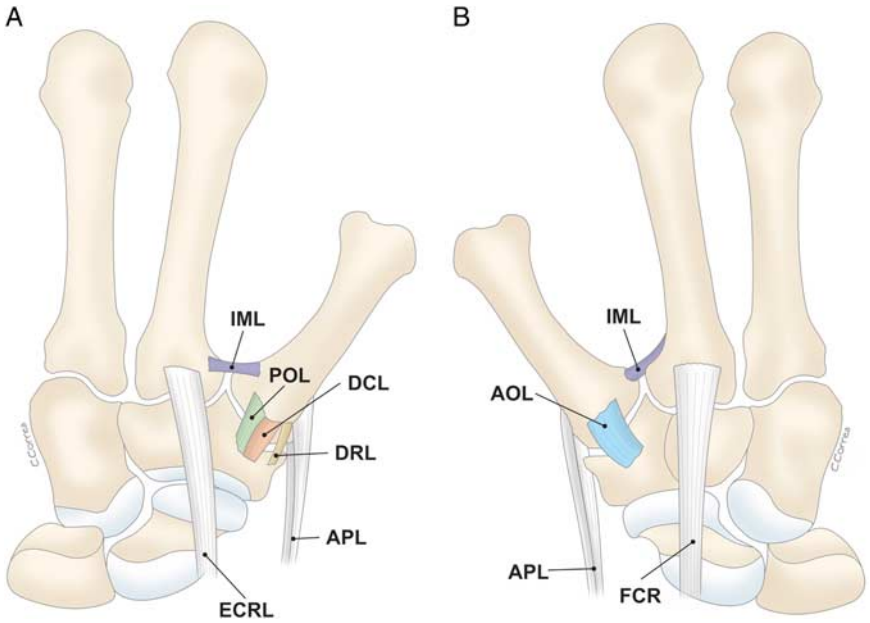

FIGURE 1. A, Dorsal view of CMC-1j. The dorsal ligament group of right CMC. IML Intermetacarpal Ligament, POL Posterior Oblique Ligament, DCL Dorsal Central Ligament, DRL Dorsal Radial Ligament, APL Abductor Pollicis Longus and ECRL Extensor Carpi Radialis Longus. B. Volar view. The volar ligament group of right CMCJ. Anterior oblique Ligament Anterior Oblique Ligament, IML Intermetacarpal ligament, APL Abductor Pollicis Longus and FCR Flexor Carpi Radialis.

From the *Hand Surgery, Clinica las Américas, Medellin, Antioquia, Colombia; †Hand & Microsurgery Unit, Jewish Hospital of Rome, Rome; ‡Rimini Hand and Upper Limb Surgery & Rehabilitation Center, Rimini; and §Pro-Mano, Hand Surgery and Rehabilitation, Treviso, Italy.
The authors report no conflicts of interest and no source of funding.
Address correspondence and reprint requests to Fabio Andrés Tandioy-Delgado, MD, Hand Surgery, Clinica las Américas, Medellin, Antioquia, Colombia. E-mail: mdfabiotandioy@gmail.com.
Supplemental Digital Content is available for this article. Direct URL citations appear in the printed text and are provided in the HTML and PDF versions of this article on the journal's website, www.techhandsurg.com.

FIGURE 2. Different projections are important using a conventional X-ray as facture lines can be hidden due to the overlapping of the carpal bones.

high-energy trauma such as during car accidents, or, seldom, by lower energy trauma such as falls. Because of the increasing frequency of high-energy trauma, the association of trapezium fractures with a fracture of the distal radius, and either, a fracture of the thumb metacarpal base (Rolando fracture), or a fracture-dislocation (Bennett fracture) is becoming very common.[7] CMC-1j dislocation is rather unusual, accounting for only 1% of all hand injuries, and therefore, is often misdiagnosed.

Very little has been published about the association of trapezium fractures with Bennett fracture-dislocations.[3,5,7–15] Traditional treatment options to this date include, closed reduction and fixation with Kirschner wires, or open reduction and internal fixation. Recently, Marcovici et al [16] described an arthroscopic technique to assist the reduction of Bennett and Rolando fractures. Arthroscopy showed the advantage of ensuring a perfect reduction of the articular surface while avoiding additional capsular or ligament damage and preserving blood supply to bone fragments.

ANATOMY

The first CMC-1j plays a key role in the prehensile function of the hand. The 2 articulating surfaces of the trapezium and the first metacarpal are shaped in a peculiar saddle configuration, [17] which allows for a broad arc of motion in flexion-extension and abduction-adduction movements. Prono-supination requires rotation and translation of the joint surfaces based on morphology and muscular activity. As the trapezial and metacarpal surfaces are only congruent at the extremes of motion,[18–21] the overall articular congruence is minimal. The stability of the CMC-1j relies on: 1) static stability which is supported by the periarticular ligaments, and 2) dynamic stability provided by the muscles moving the joint. Therefore, the CMC-1j, being an inherently hypermobile joint, bases its stability on the proprioceptive function of its periarticular ligaments and muscles.

Ligamentous stability of the CMC-1j is provided by 7 ligaments (Fig. 1). The Anterior oblique Ligament (AOL), intermetacarpal ligament (IML), and DorsoRadial Ligament (DRL) are currently considered the most important.

The Dorsal Radial Ligament (DRL) is the main stabilizing ligament, as it is the strongest and most rigid in the CMC-1j.[22–26]

By showing that the dorsal ligaments have more nerve endings than the anterior ligaments, Hagert et al [26] recognized that the DRL is fundamental in initiating the proprioceptive response that provides dynamic stability to the joint. The more important muscles to support stability in the joint are: 1) the first Dorsal Interosseous, Extensor Pollicis Longus (EPL), Abductor Pollicis Longus (APL), and Abductor Pollicis Brevis . The first Dorsal Interosseous stabilizes the proximal part of the first metacarpal towards the ulnar side, the Abductor Pollicis Brevis positions the thumb in opposition, and the APL and Extensor Pollicis Longus work as balancing antagonists between abduction and adduction.

INDICATION, CONTRAINDICATION, AND PREOPERATIVE EVALUATION

In this paper, we describe a technique of arthroscopic assistance in the treatment of intra-articular fractures of the CMC-1j. This technique is indicated for treating isolated trapezium fractures, or more complex conditions such as the combination of a trapezium fracture with either a Bennet and even Rolando fractures. The technique is contraindicated when the skin of the thumb is damaged or hypotrophic, because of the fact that the procedure requires the use of a finger trap for thumb traction.

Preoperatively, a detailed patient history and information on the mechanism of injury are taken. X-rays (Fig. 2) and a CT scan (Fig. 3) are useful for a thorough assessment of the fracture pattern, especially since fracture fragments are often small. In addition, an MRI examination may improve the diagnosis of concurrent ligament damage.

SURGICAL TECHNIQUE

Patient Positioning and Equipment

The patient is placed in a supine position and a tourniquet is placed on his arm. The shoulder and elbow are then positioned

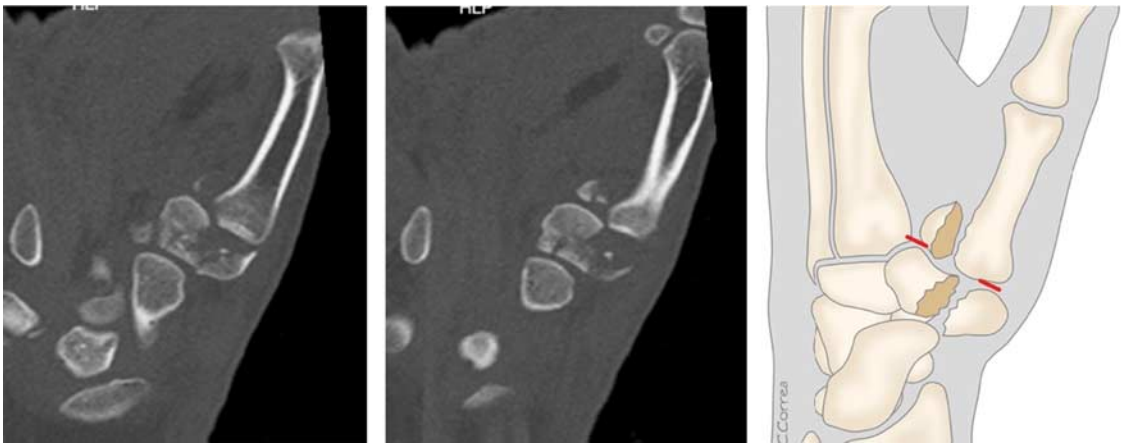

FIGURE 3. For Bennett and trapezium fractures, a CT scan is recommended to get a better detailed view and understanding of every piece of bone. In these cases, the surgeons can see the fracture from different directions and can plan the surgery better.

at a 90 degrees abduction, and a 90 degrees flexion respectively, with the hand in a vertical position. Traction is applied to the thumb and index finger using a wrist tower with a 2 kg traction. The traction device should allow movement of the wrist and thumb, so the surgeon is able to work around the CMC-1j. It is recommended that the surgical assistant support the hand to maintain the supine position. A 1.9 mm arthroscope is the best size to explore the CMC-1j, and dry arthroscopy is performed to avoid swelling of the soft tissues.[27–29]

Creation of the Portals

Arthroscopic assessment is performed as described by Marcovici et al[16] The box concept of the CMC-1j (Fig. 4) is applied to confirm the proper positioning of all the portals.[16,30] The main working portals are the 1R, located radial to the Abductor Pollicis Longs tendon, and the 1U, located ulnar to the Pollicis Brevis Extensor tendon, within the first dorsal compartment.[16,30–36] A 21G needle is used to locate each portal before the skin incision. The needles should be introduced at a 0 degree to 10 degrees distal tilt. Fluoroscopy is often used to confirm the needles' positions before the insertion of the arthroscope.[16,17] Fluoroscopy also shows the amount of preliminary reduction of the dislocation and fragment displacement, following the ligamentotaxis provided by thumb distraction. The arthroscope is introduced with the same orientation as the needles and switched between the portals following the "box concept" to achieve complete vision of

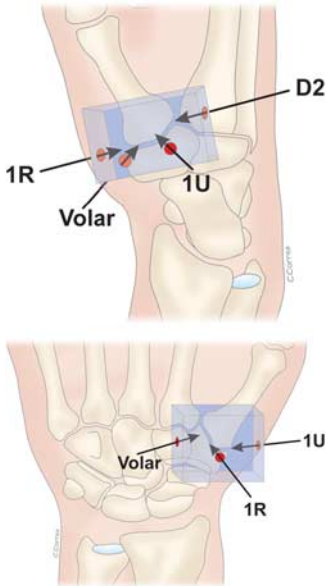

FIGURE 4. The Box Concept for the CMC-1J. The 1-radial (1R) portal is located radial to the abductor Pollicis Longus tendon. The 1-ulnar (1U) portal is just posterior-ulnar to the Extensor Pollicis Brevis tendon. The dorsal distal portal (D2) lies just distal of the dorsal intermetacarpal. The box concept adapted from "Arthroscopic Assisted Treatment of Thumb Metacarpal Base Articular Fractures" by Marcovici et al.[16]

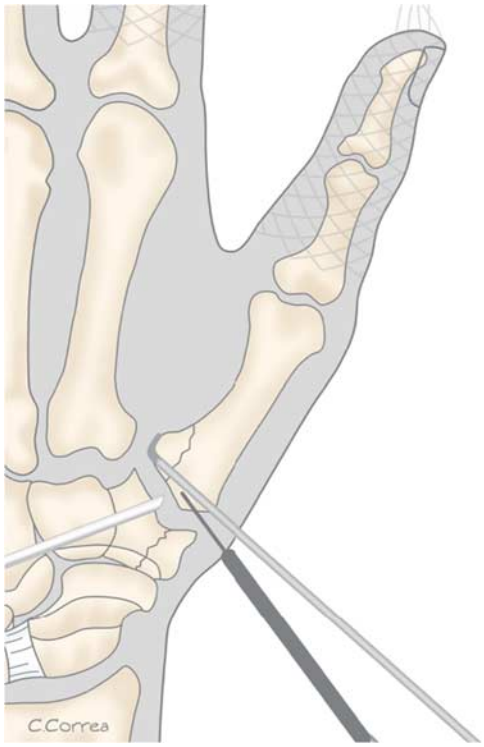

FIGURE 5. The hook helps to reduce the fracture and 1 K-wire is used to fix it.

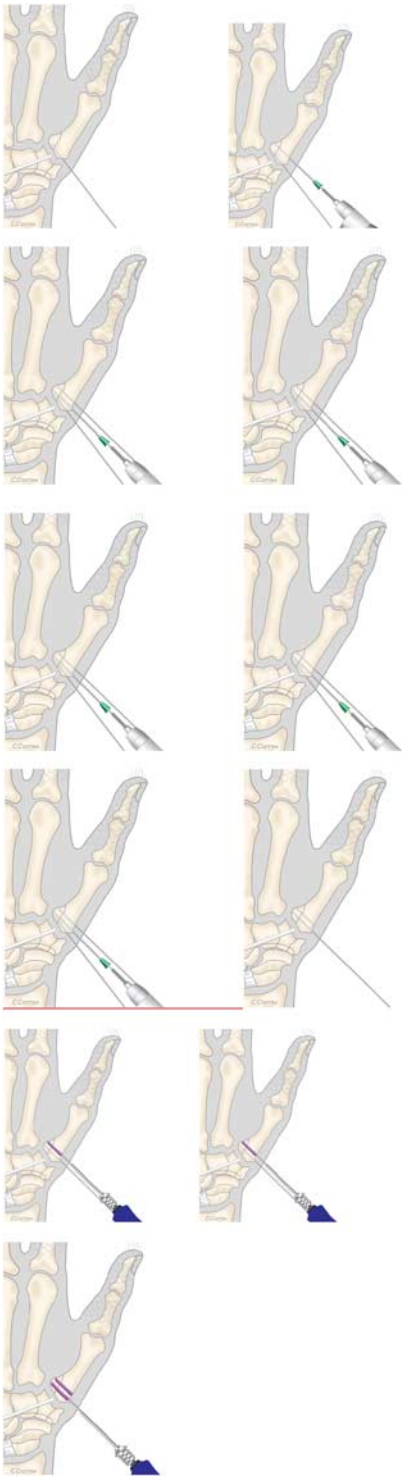

FIGURE 6. One K-wire was used close to the subcondral area to fix the fracture, and 2 more K-wires were positioned to achieve a perfect reduction. After which, these were changed for 2 screws. The scope and fluoroscopy are continuously used to avoid damaging the cartilage when the K-wire and screw are applied.

the joint. Thorough joint exploration is mandatory to confirm the intra-articular fracture lines as demonstrated by the preoperative CT scan, and any ligament injuries of the CMC-1j.

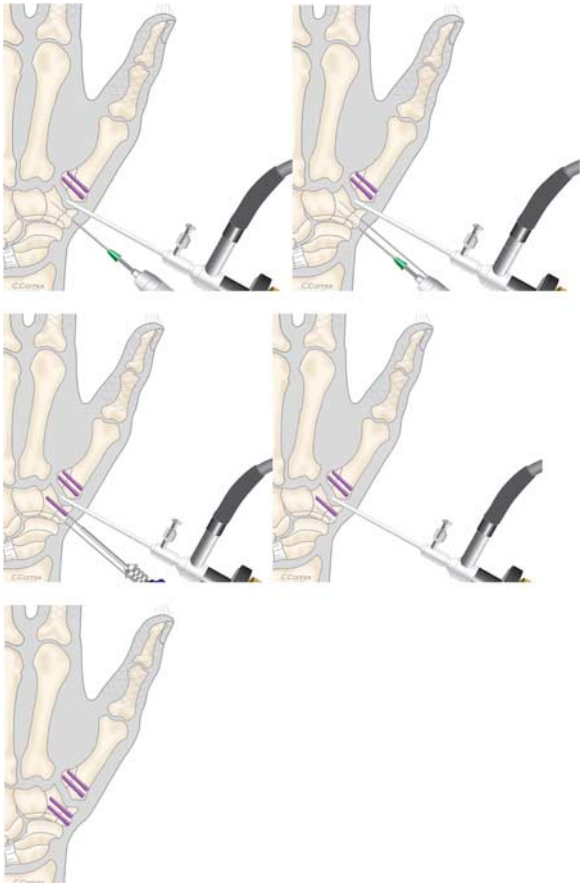

FIGURE 7. The same methodology was used to repair the trapezium. First the K-wire was applied, then they were changed for 2 screws and the scope and fluoroscopy were used to evaluate their position and avoid further injury to the cartilage.

Reduction Technique of Bennett and Trapezium Fractures

To reduce a Bennett fracture, the arthroscope is placed in the 1-U portal and a probe in the 1-R portal. The fragment is elevated with the help of the probe until an anatomical reduction is reached (Fig. 5). Then, a provisional fragment fixation is achieved using percutaneous Kirschner wires. A 21G needle is introduced into the arthroscopic portals as a guide to facilitate the procedure (Fig. 6). Once the K-wire positions are verified with fluoroscopy, 2 1.2 mm cannulated screws are used over the wires for final fixation (Fig. 6).

Following this, the trapezium fracture is approached. The probe or a freer elevator is used to reduce the intra-articular fracture fragments, and the same procedure is followed using K-wires and screws. (Figs. 5–7 and video Supplemental Digital Content 1, http://links.lww.com/BTH/A181, which demonstrates the reduction of the Bennett and trapezium fractures by arthroscopy).

In addition, as this fracture may be associated with severe ligamentous injury, joint dislocating manual maneuvers are executed after fixation to rule out any residual instability of the CMC-1j. After proper fracture reduction and fixation gross instability, requiring ligament repair, is rather unusual. When slight to mild hyperlaxity still persists, the postoperative rehabilitation should be postponed for 3 weeks postoperatively.

FIGURE 8. Four days after surgery. Mild swelling and the small incisions can be seen.

The portal incisions are closed with 4-0 nonabsorbable sutures and a soft bandage is wrapped around the area.

Postoperative Management

Three days after surgery, the bandages are removed, and thumb mobility is permitted, but only within a painless range of motion (ROM). An early, independent increase in the ROM is encouraged. To protect the fixation, active clamping, grasping, and similar forceful activities are restricted for 2 to 3 weeks according to the perceived strength of the fixation (Fig. 8 and video supplemental digital content 2, http://links.lww.com/BTH/A182, which demonstrates active unloaded mobility in the thumb in the immediate days after surgery). Formal rehabilitation is initiated at 3 weeks postoperatively. Early skin massage of the portal sites is recommended, especially if the patient reports some distal numbness or skin discomfort around the 1R portal. This happens as the terminal branches of the superficial radial nerve may have been irritated during surgery.

EXPECTED OUTCOMES

A thorough review of the literature was carried out; however, a case of arthroscopy fixation of a trapezium and Bennett fracture could not be identified. In this specific case, the patient showed a full recovery in the movement of the thumb 1 month after surgery (Fig. 9 and video supplemental digital content 3, http://links.lww.com/BTH/A183, which demonstrates full thumb mobility). The patient returned to full laboral activities 7 weeks after surgery, and was able to complete ADL tasks with minimal exertional pain. One year after the fracture, the patient is able to make a full ROMs with his thumb and does not exhibit any restrictions. In addition, full, painless pinch strength has resumed. The patient expresses high satisfaction with the results.

COMPLICATIONS

There are few publications in reference to treating trapezium, Bennet, or even Rolando fractures using arthroscopic assistance. However, complications may arise because of the arthroscopy technique itself, or the way the fracture is treated.

In relation to the technical type of complication, it should be mentioned that the Dorsal Sensitive Radial nerve may be irritated when the surgeon creates the 1R portal; nevertheless, it will resolve with time. In addition, the Abductor Pollicis Longus and Extensor Pollicis Brevis may be injured if the surgeon does not properly identify them before accessing the portals. Another complication is damage to the cartilage, which could occur if the arthroscope is introduced forcefully at an incorrect angle of inclination. Furthermore, injury to the radial artery is possible when the portals are used incorrectly. Finally, some patients experience scar tenderness as the wound is healing.

Other possible complications may occur during the treatment of the fracture: deep infection of the wound and skin might occur, and also a step-off or rotation of the fracture because of an inappropriate reduction. On the other hand, incorrect location and orientation of the screws can cause screw protrusion in the joint or under the skin, which will cause pain and discomfort when moving the thumb.

DISCUSSION

Fractures of the CMC-1j are rare and occur following a high-energy trauma on the thumb axis. Fundamentally, 2 traumatic mechanisms are recognized as varying forces, and the impact angles result in a combination of a Bennett fracture-dislocation and trapezium fracture.[4,37] First, the axial load on the first metacarpal results in the impaction of the trapezium between the metacarpal and the radial styloid, producing either a vertical split or a comminuted fracture of the trapezium. An avulsion of the anterior oblique ligament from the volar ulnar aspect of the base of the first metacarpal may also be associated. The other mechanism that produces the Bennett fracture involves an abduction force through the first web space, which may occur after an axial force with flexion on the first metacarpal, such as during sudden deceleration when riding a motorcycle, or during a fall when holding an object in the hand.

Trapezium fractures have been classified by Walker et al[38] into 5 types (Fig. 10). Most of the trapezium fractures associated with Bennett fracture-dislocation have been classified as a type IIa, IIb or IV. In these cases, it is important to obtain appropriate x-ray views because the overlapping of the carpal bones may obscure some fracture lines. Robert's view, a true anteroposterior view of the CMC-1j, is recommended in this case. A CT scan should be performed to get detailed information on the comminution and dislocation. The goal of the treatment in this type of injury is to achieve a stable joint, with an anatomic reduction and stable fixation.

Different techniques have been used for the treatment of these injuries, varying from closed reduction and cast immobilization, closed reduction and percutaneous pinning, to open reduction and ligament reconstruction. Because of the combination of a trapezium fracture and a Bennett fracture-dislocation, open reduction is the treatment of choice in most cases to achieve proper intra-articular reduction and ligament repair. However, because of the small joint size and post-traumatic swelling, a standard CMC-1j exposure may not allow for a clear assessment of the joint surfaces. Consequently, an

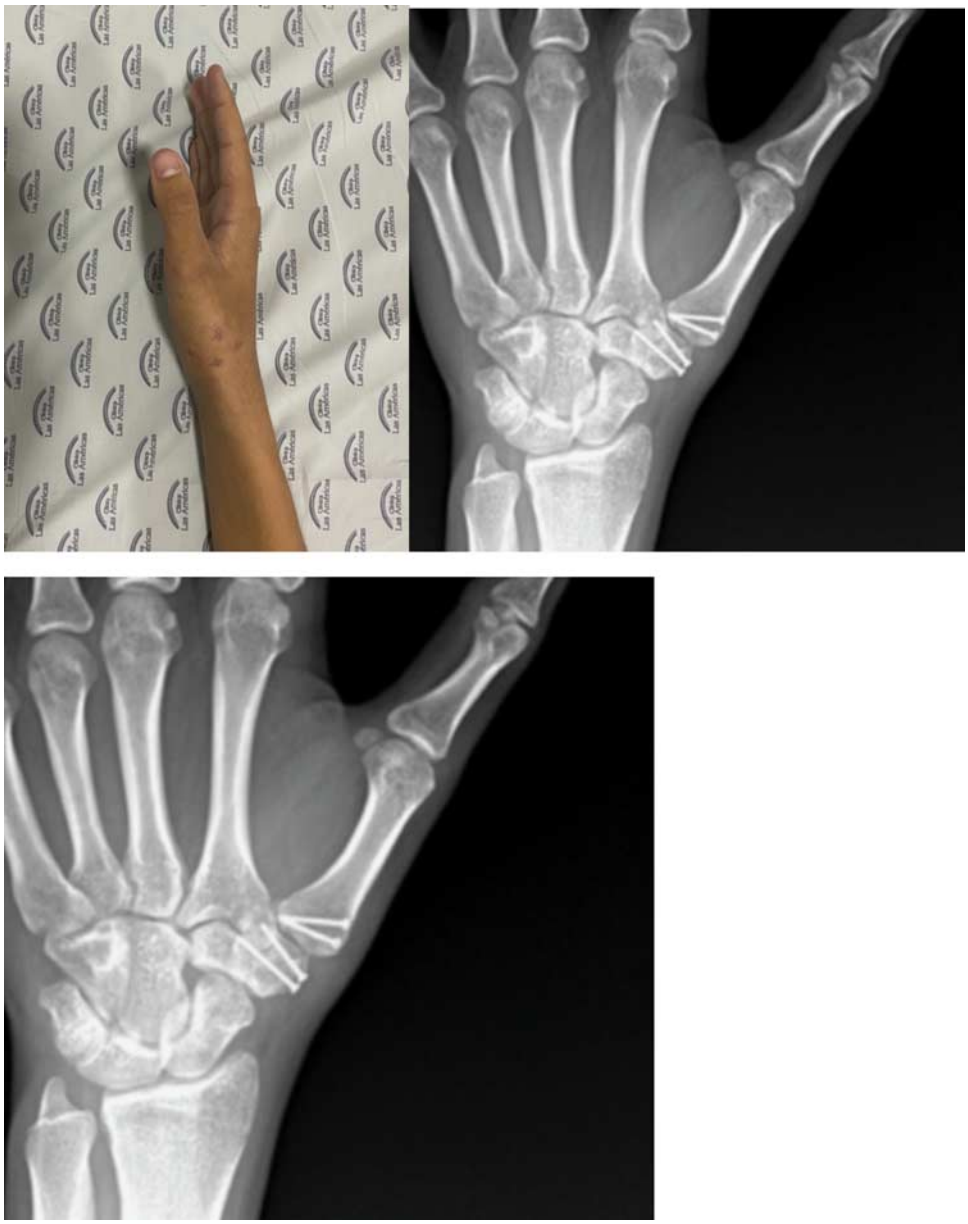

FIGURE 9. The photo and X-rays show the small incisions and consolidation of the fracture.

extended exposure is most likely to be required, which produces an extensive periarticular soft-tissue laceration, including additional ligamentous damage. Therefore, minimally invasive methods should be recommended for these complex cases.

In this case report, an arthroscopic assisted technique was adopted as a minimally invasive approach to reduce intra-articular incongruence. Percutaneous screws were used to provide a primary stable fixation. The first reports of arthroscopy of the CMC-1j were presented by Berger in the AAOS/ASSH course of Wrist Joint Arthroscopy in Chicago in 1995.[30] A year later, Luchetti and Berger[31] first described the arthroscopic technique on an articular CMC-1j fracture. However, the first international publication was made in 1997, in which 4 patients with Bennett fracture-dislocations were treated by arthroscopy.[32] More recently Marcovici et al [16] described the technical details of arthroscopic assistance to articular fractures of the thumb metacarpal base.

As the literature is lacking articles dealing with the treatment of a combined intra-articular fracture of the trapezium and the base of the first metacarpal with a CMC-1j dislocation (Bennett fracture), this paper adds a new minimally invasive option to the armamentarium of the hand surgeon facing this scenario by introducing the use of arthroscopic assistance.

Arthroscopically assisted reductions of CMC-1j fractures offer many advantages. Firstly, it allows an anatomic reduction of the trapezium and Bennett fracture by direct visualization and magnification of the fractures. Secondly, it gives the option to assess the capsule and ligaments, without any additional surgical damage. If the dorsal capsular ligament is intact and correctly inserted to the bone, a stable joint can be observed. On the other

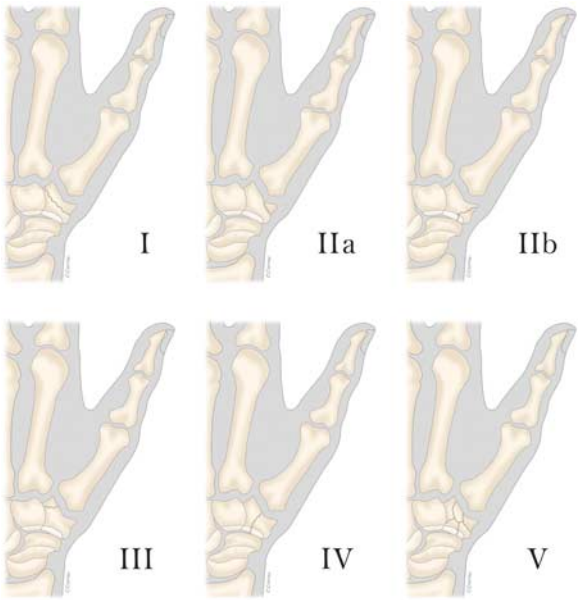

FIGURE 10. Classification of Trapezium Fractures. Adapted from "Fractures of the body of the trapezium" by J. L. Walker, et al.[38] Copyright 1988 by Raven Press, Ltd., New York.

hand, if the ligament is damaged, it can be repaired at the same time as the fracture, avoiding postoperative complications or the need for a secondary ligament reconstruction.[39–42] Great advantages come from the use of arthroscopy. Through the use of small incisions, enhanced accuracy of each procedure of fracture reduction and fixation is assured by the magnification provided by the arthroscope. The minimally invasive approach permits fracture fragment viability, ensuring faster fracture healing, and avoiding additional damage to the periarticular soft tissues, preserving joint stability and ensuring a faster recovery after surgery.

Introducing arthroscopic assistance to the treatment of this type of concomitant injuries allows one to benefit from the many advantages of a minimally invasive approach without sacrificing the quality and primary stability of the bone fixation. The reason that this treatment option was chosen is that this technique reduces injury to the capsule and ligaments around the fracture, provides a better visualization of the entire articular fractures, and ensures better articular stability of the joint. Additional advantages of this intervention are a faster recovery, less postoperative pain, small skin incisions resulting in indiscreet cosmetic scars, and less stiffness.

Limitations of this study are that only a single patient was treated. However, because of the unusual combination of these fractures, a large number of patient case studies is unlikely to be collected.

In conclusion, trapezium fractures associated with Bennett fracture-dislocation are an unusual finding in clinical practice and they may be easily overlooked. Therefore, an adequate history, physical examination, and image studies are very important in the diagnosis and treatment of these injuries. Indications to an arthroscopic approach in wrist and hand injuries are broadening because of the great number of advantages provided by magnified direct visualization of the fracture and ligament structures, which is key to achieving an anatomic reduction of intra-articular fractures and accurate ligament repair. Arthroscopy not only allows surgeries to be performed through small incisions, but also protects the capsule, the ligaments, and soft tissues around the joint. Periarticular muscles and the mechano-receptive nerve endings that innervate the CMC-1j ligaments, particularly the dorsoradial ligament, form the proprioceptive system, which is responsible for the neuromuscular control of the CMC-1j. Because of its particular saddle shape, the CMC-1j is inherently unstable and relies on the dynamic control provided by the ligamento-muscular reflexes to maintain both mobility and stability.[24–26,43] Minimally invasive, arthroscopic surgery has the advantage of preserving the proprioceptive system by avoiding unnecessary additional damage of the periarticular soft tissues. Consequently, it guarantees a fast, optimal, and functional recovery of the patient.

This case report confirms that arthroscopic assistance is a safe, mini-invasive method, which can be used to treat a combined fracture of the trapezium and the base of the first metacarpal, as it permits anatomic intra-articular reduction and preservation of the soft tissues around the CMC-1j, thus allowing for a faster recovery after surgery.

REFERENCES

1. Borgeskov S, Christiansen B, Kjaer A, et al. Fractures of the carpal bones. *Acta Orthop Scand*. 1966;37:276–287.
2. Panigrahi R, Biswal MR, Palo N, et al. Isolated coronal fracture of trapezium- a case report with review of literature. *J Orthop Case Rep*. 2015;5:29–31.
3. Ramoutar DN, Katevu C, Titchener AG, et al. Trapezium fracture a common technique to fix a rare injury: a case report. *Cases J*. 2009;2:8304.
4. Kose O, Keskinbora M, Guler F. Carpometacarpal dislocation of the thumb associated with fracture of the trapezium. *J Orthop Traumatol*. 2015;16:161–165.
5. Tolat AR, Jones MW. Carpometacarpal dislocation of the thumb associated with fracture of the trapezium. *Injury*. 1990;21: 411–412.
6. Alonso L, Couceiro J. Comminuted fracture of the body of the trapezium and thumb carpometacarpal dislocation: a particular pattern. *Surg J (N Y)*. 2018;4:e34–e36.
7. Garneti N, Tuson CE. Sagittally split fracture of trapezium asso- ciated with subluxated carpo-metacarpal joint of thumb. *Injury*. 2004;35:1172–1175.
8. Chamseddine A, Hamdan H, Zein H, et al. Fracture of trapezium with trapeziometacarpal subluxation. *Eur J Orthop Surg Traumatol*. 2009;19:499–503.
9. Afshar A, Mirzatoloei F. Carpometacarpal joint dislocation of the thumb associated with the fracture of the trapezium. *Arch Iran Med*. 2006;9:282–283.
10. Mumtaz MU, Drabu NA. Open complete dislocation of trapezium with a vertically split fracture: a case report. *Cases J*. 2009;2:9092.
11. Parker WL, Czerwinski M, Lee C. First carpal-metacarpal joint dislocation and trapezial fracture treated with external fixation in an adolescent. *Ann Plast Surg*. 2008;61:506–510; Garavaglia G, Bianchi S.
12. Santa DD, Fusetti C. Trans- trapezium carpo-metacarpal dislocation of the thumb. *Arch Ort- hop Trauma Surg*. 2004;124:67–68.
13. Kukreti S, Harrington P. Carpometacarpal joint dislocation of the thumb associated with fracture of the trapezium: a case report. *Eur J Orthop Surg Traumatol*. 2004;14:38–39.
14. Mody BS, Dias JJ. Carpometacarpal dislocation of the thumb associated with fracture of the trapezium. *J Hand Surg Br*. 1993;18:197–199.
15. Morizaki Y, Miura T. Unusual pattern of dislocation of the trapeziometacarpal joint with avulsion fracture of the trapezium: case report. *Hand Surg*. 2009;14(2–3):149–152.

16. Marcovici LL, Atzei A, Cozzolino R, et al. Arthroscopic assisted treatment of thumb metacarpal base articular fractures. *Arthrosc Tech*. 2021;10:e1783–e1792.
17. Napier JR. The form and function of the carpo-metacarpal joint of the thumb. *J Anat*. 1955;89:362–369.
18. Haines RW. The mechanism of rotation at the first carpometacarpal joint. *J Anat*. 1944;78(pt 1–2):44–46.
19. Pellegrini VD Jr. Osteoarthritis and injury at the base of the human thumb: Survival of the fittest? *Clin Orthop Relat Res*. 2005;438:266–276.
20. Haara MM, Heliövaara M, Kröger H, et al. Osteoarthritis in the carpometacarpal joint of the thumb: Prevalence and associations with disability and mortality. *J Bone Joint Surg Am*. 2004;86:1452–1457.
21. Matullo KS, Ilyas A, Thoder JJ. CMC arthroplasty of the thumb: a review. *Hand (N Y)*. 2007;2:232–239.
22. Bettinger PC, Linscheid RL, Berger RA, et al. An anatomic study of the stabilizing ligaments of the trapezium and trapeziometacarpal joint. *J Hand Surg Am*. 1999;24:786–798.
23. Bettinger PC, Smutz WP, Linscheid RL, et al. Material properties of the trapezial and trapeziometacarpal ligaments. *J Hand Surg Am*. 2000;25:1085–1095.
24. Ladd AL, Lee J, Hagert E. Macroscopic and microscopic analysis of the thumb carpometacarpal ligaments: a cadaveric study of ligament anatomy and histology. *J Bone Joint Surg Am*. 2012;94:1468–1477.
25. D'Agostino P, Kerkhof FD, Shahabpour M, et al. Comparison of the anatomical dimensions and mechanical properties of the dorsoradial and anterior oblique. *J Hand Surg Am*. 2014;39:1098–1107.
26. Hagert E, Lee J, Ladd AL. Innervation patterns of thumb trapeziometacarpal joint ligaments. *J Hand Surg Am*. 2012;37:706–714; e1. Set -up, portals and normal exploration in wrist arthroscopy.
27. Atzei A, Luchetti R, Sgarbossa A, et al. Set-up, portals and normal exploration in wrist arthroscopy. *Chir Main*. 2006;25(Suppl 1):S131–S144.
28. Del Piñal F. Technical tips for (dry) arthroscopic reduction and internal fixation of distal radius fractures. *J Hand Surg Am*. 2011;36:1694–1705.
29. del Piñal F. Dry arthroscopy and its applications. *Hand Clin*. 2011;27:335–345.
30. Berger RA. *Arthroscopy of the 1st CMC (trapeziometacarpal) joint AAOS Course: current perspectives on arthroscopy of the wrist*. Rosemont, IL; 1995.
31. Luchetti R, Berger RA Valutazione artroscopica della TM in fase pre-artrosica e instabile. In: La Rizoartrosi, Monografie della Società Italiana di Chirurgia della Mano. Parma: Mattioli Editore, 1996. p:53-63.
32. Berger RA. Technique for arthroscopic evaluation of the first carpometacarpal joint. *J Hand Surg*. 1997;22A:1077–1080.
33. Gonzalez MH, Kemmler J, Weinzweig N, et al. Portals for arthroscopy of the trapeziometacarpal joint. *J Hand Surg*. 1997;22B:574–575.
34. Luchetti R, Berger RA Valutazione artroscopica della TM in fase pre-artrosica e instabile. In: La Rizoartrosi, ed. *Monografie della Società Italiana di Chirurgia della Mano*. Parma: Mattioli Editore, 1996:53–63.
35. Luchetti R, Badia A, Orbay J, et al. Artroscopia dell'articolazione trapezio-metacarpica. In: Luchetti A, Atzei A, eds. *Artroscopia di polso*. Fidenza (Parma, Italy): Mattioli Editore; 2001:73-84.
36. Menon J. Arthroscopic management of trapeziometacarpal joint arthritis of the thumb. *Arthroscopy*. 1996;12:581–587.
37. Goyal T. Bennett's fracture associated with fracture of trapezium - a rare injury of first carpo-metacarpal joint. *World J Orthop*. 2017;8:656–659.
38. Walker JL, Greene TL, Lunseth PA. "Fractures of the body of the trapezium," *J Orthop Trauma*. 1988;2:22–28.
39. Shah J, Petal M. Dislocation of carpometacarpal joint of the thumb. *Clin Orthop Relat Res*. 1983;175:166–169.
40. Simonian PT, Trumble TE. Traumatic dislocation of the thumb carpometacarpal joint: early ligamentous reconstruction versus closed reduction and pining. *J Hand Surg Am*. 1996;21:802–806. doi:10.1016/S0363-5023(96)80195-X
41. Strauch RJ, Berhman MJ, Rosenwasser MP. Acute dislocation of the carpometacarpal joint of the thumb: an anatomic and cadaver study. *J Hand Surg Am*. 1994;19:93–98. doi:10.1016/0363-5023 (94)90229-1
42. El Ibrahimi A, Amar F, Chbani B, et al. Dislocation of the carpometacarpal joint of the thumb associated with trapezium and Bennett's fractures. *Hand*. 2009;4:191–193.
43. Mobargha N, Rein S, Hagert E. Ligamento-muscular reflex patterns following stimulation of a thumb carpometacarpal ligament: an electromyographic study. *J Hand Surg Am*. 2019;44:248.e1–248.e9.