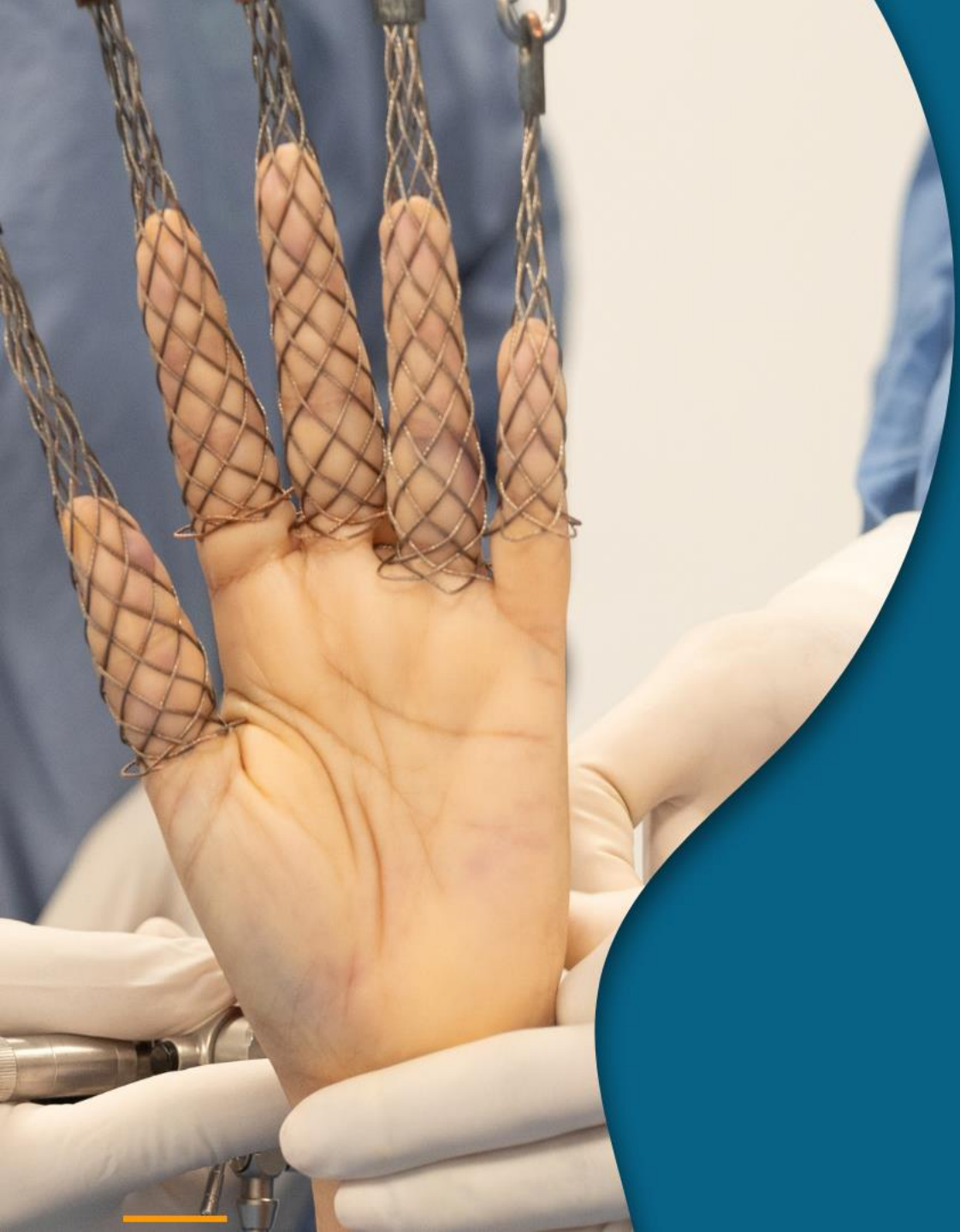



Personal Experience with Thumb Arthroscopy

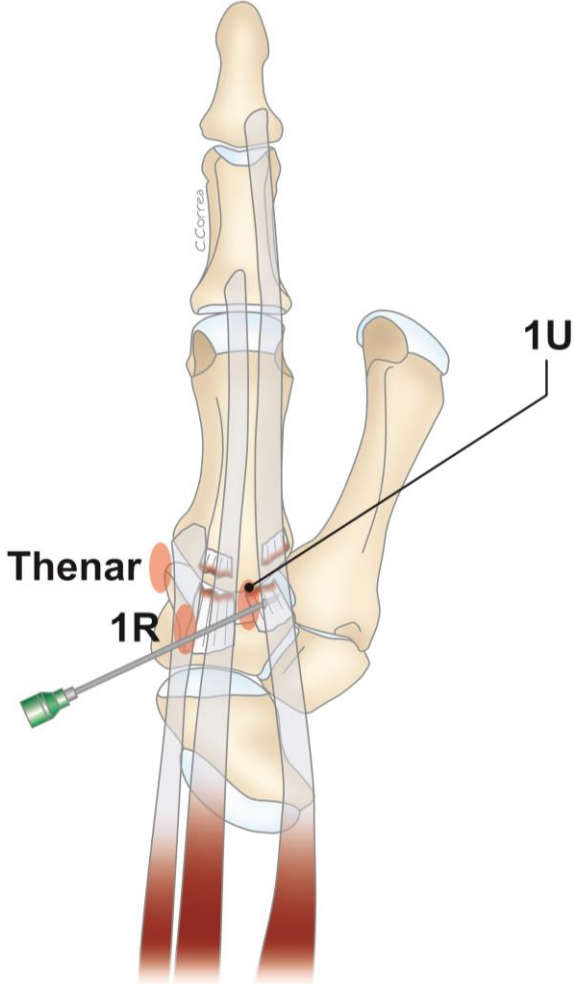
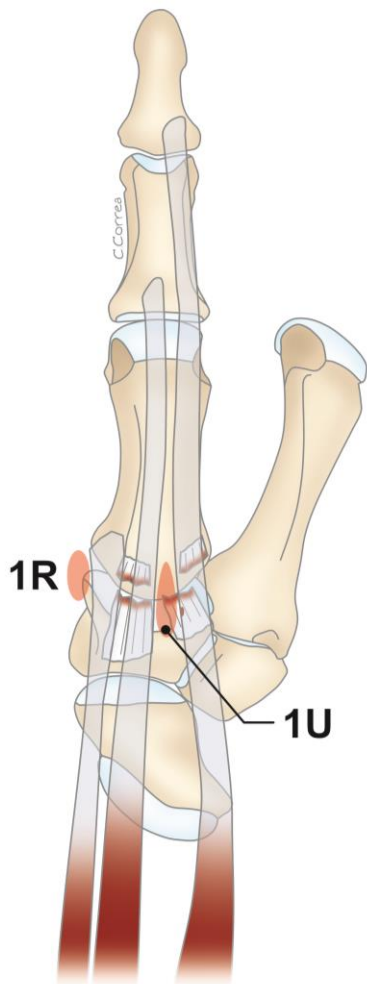


FABIO TANDIOY
CIRUJANO DE MANO

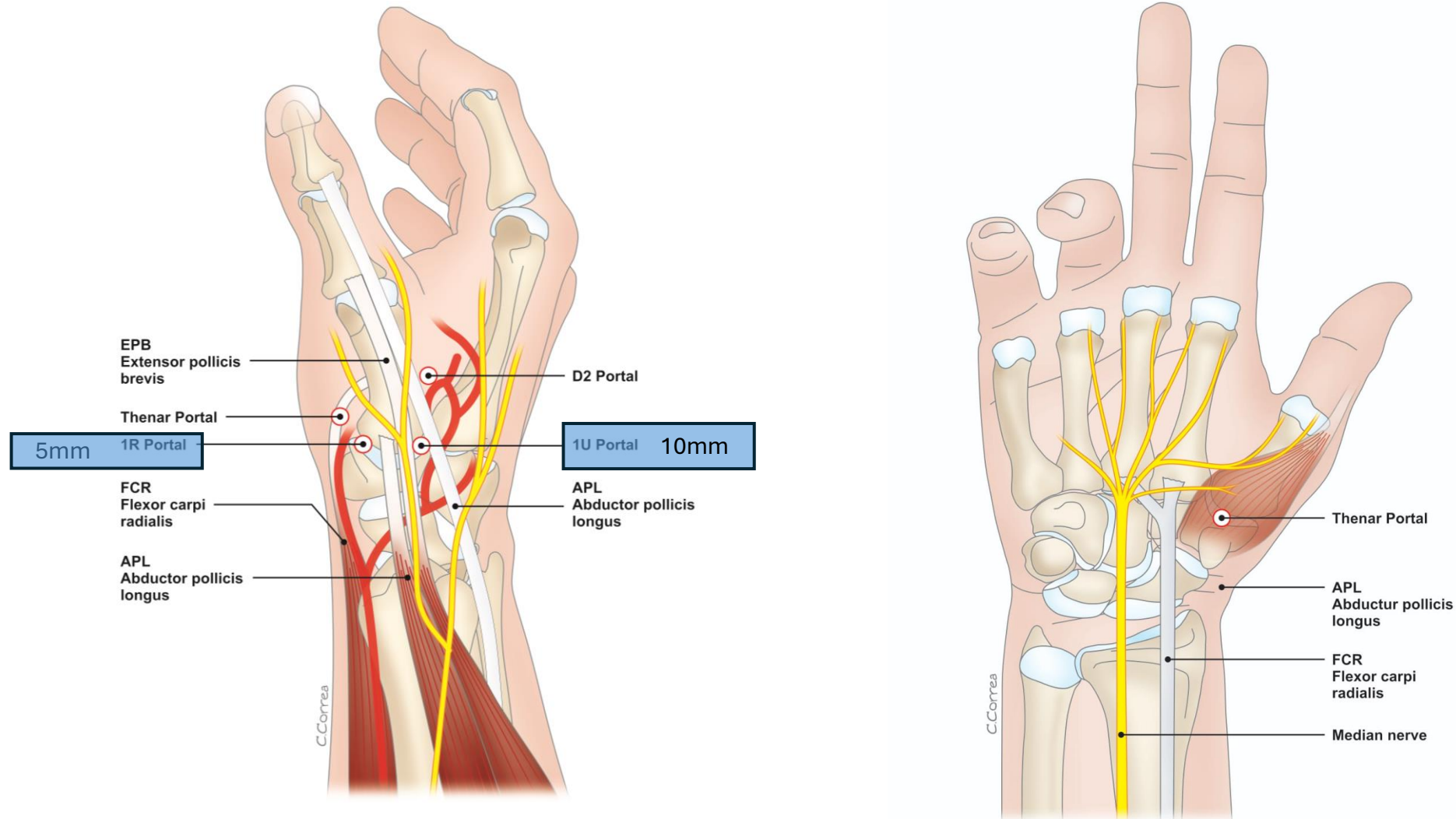


**I have no conflicts of
interest to disclose.**

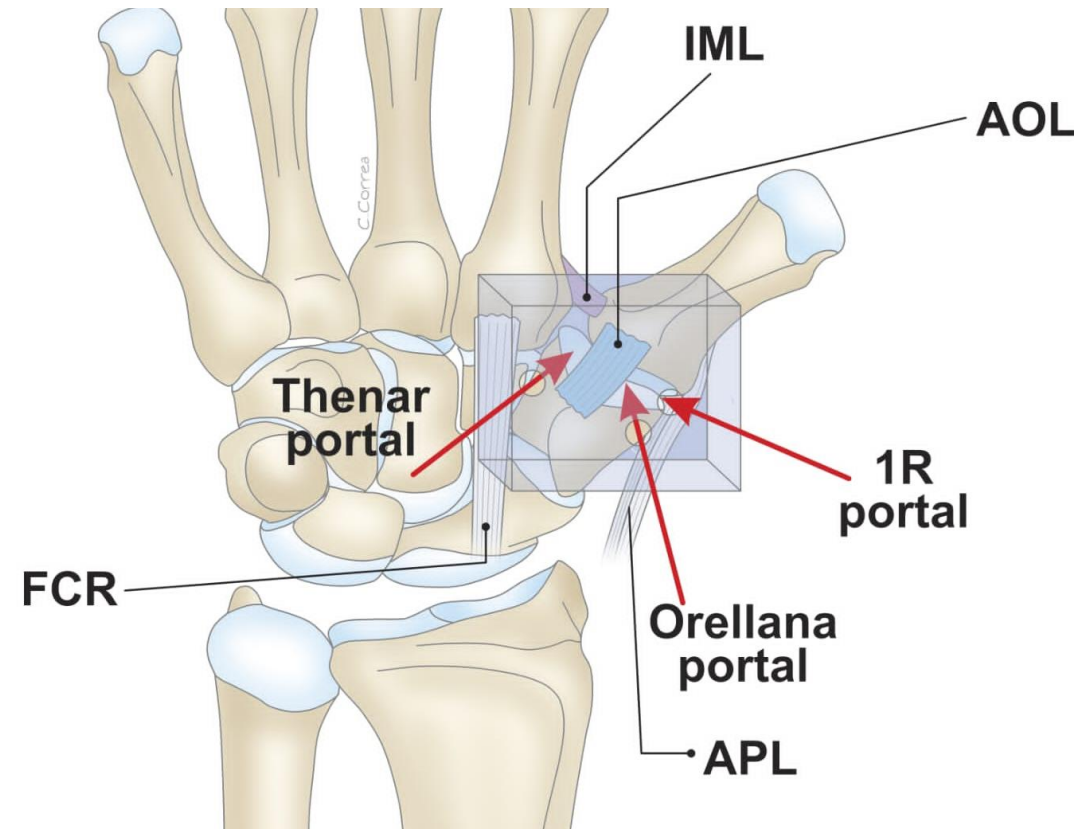
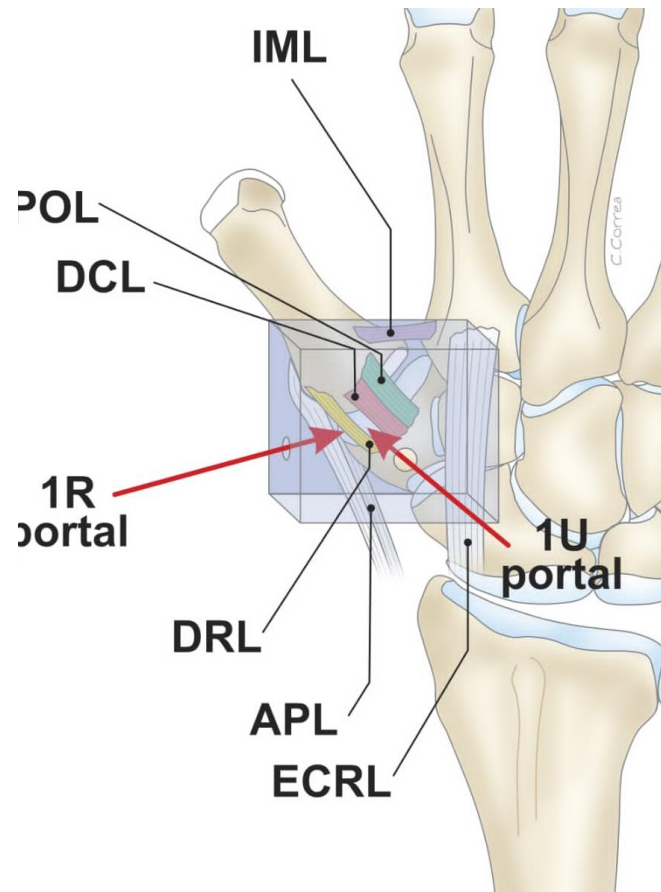
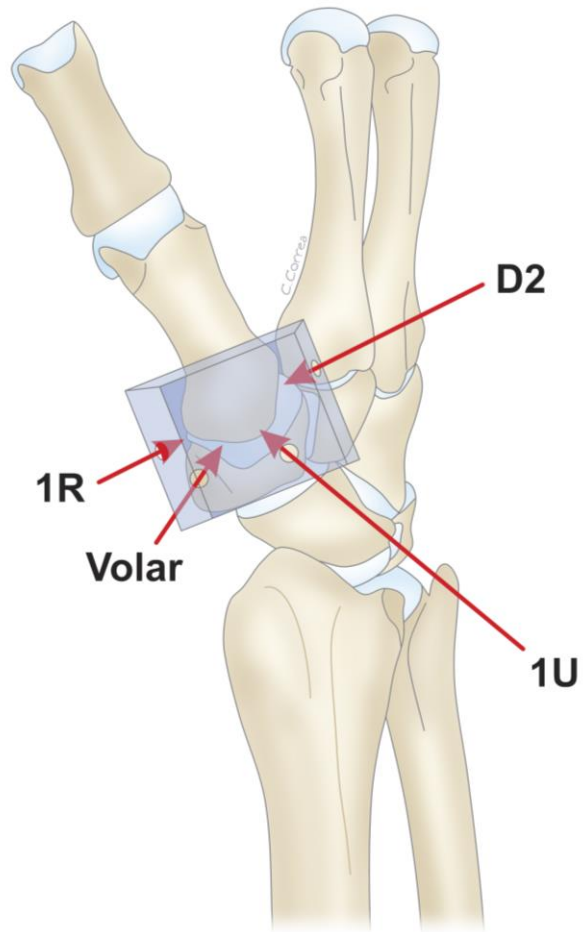
Carpometacarpal First Joint Portals



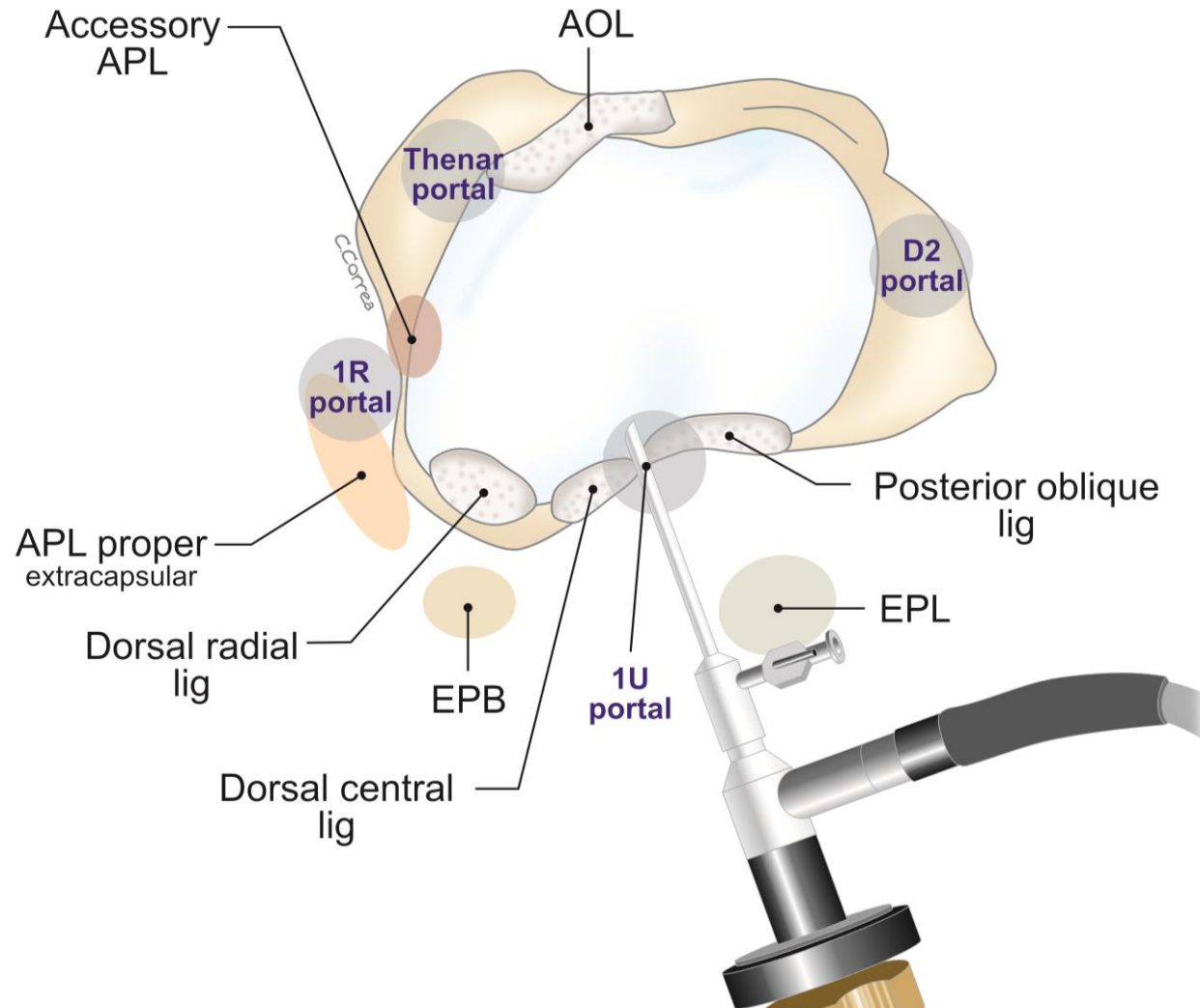
Portal Safety Around the SBRN



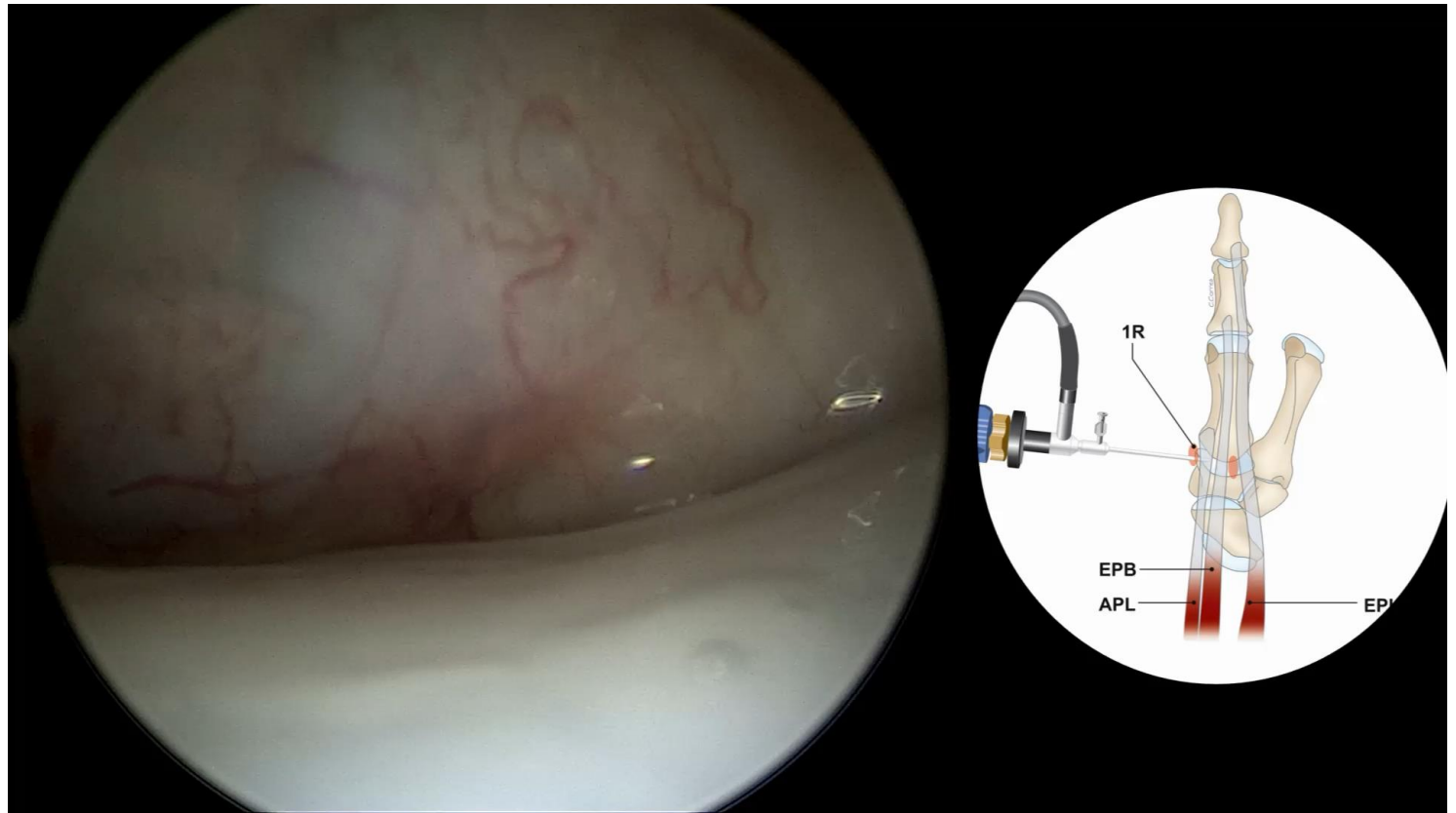
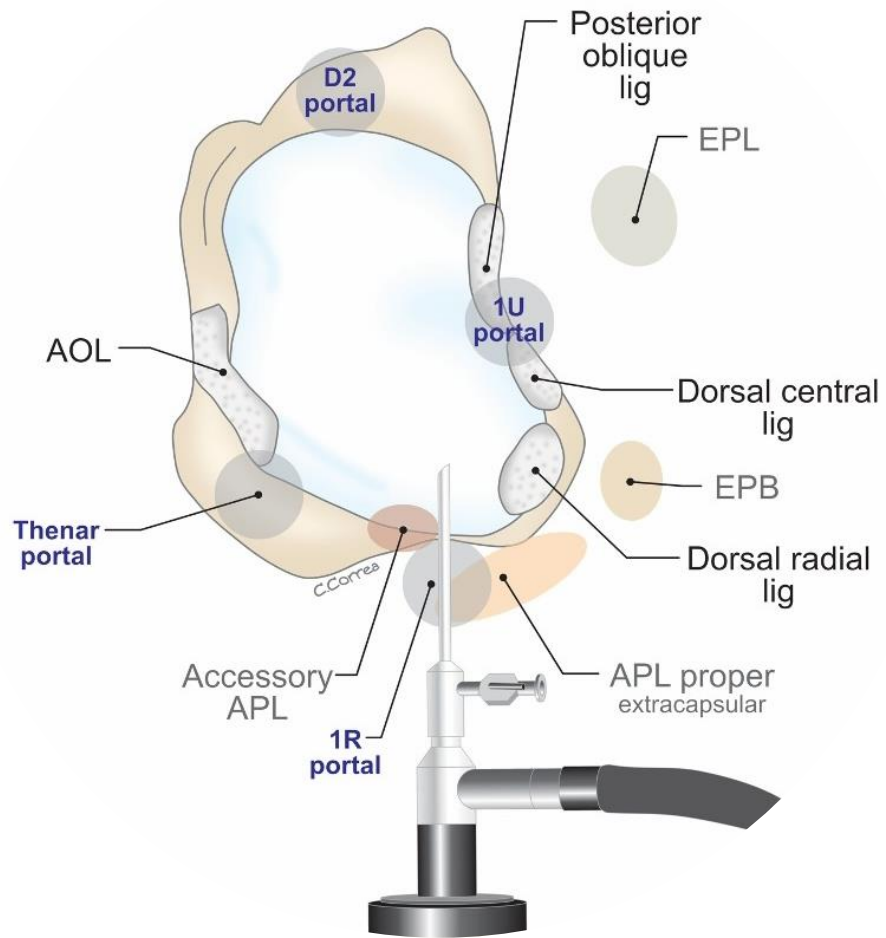
Box Concept



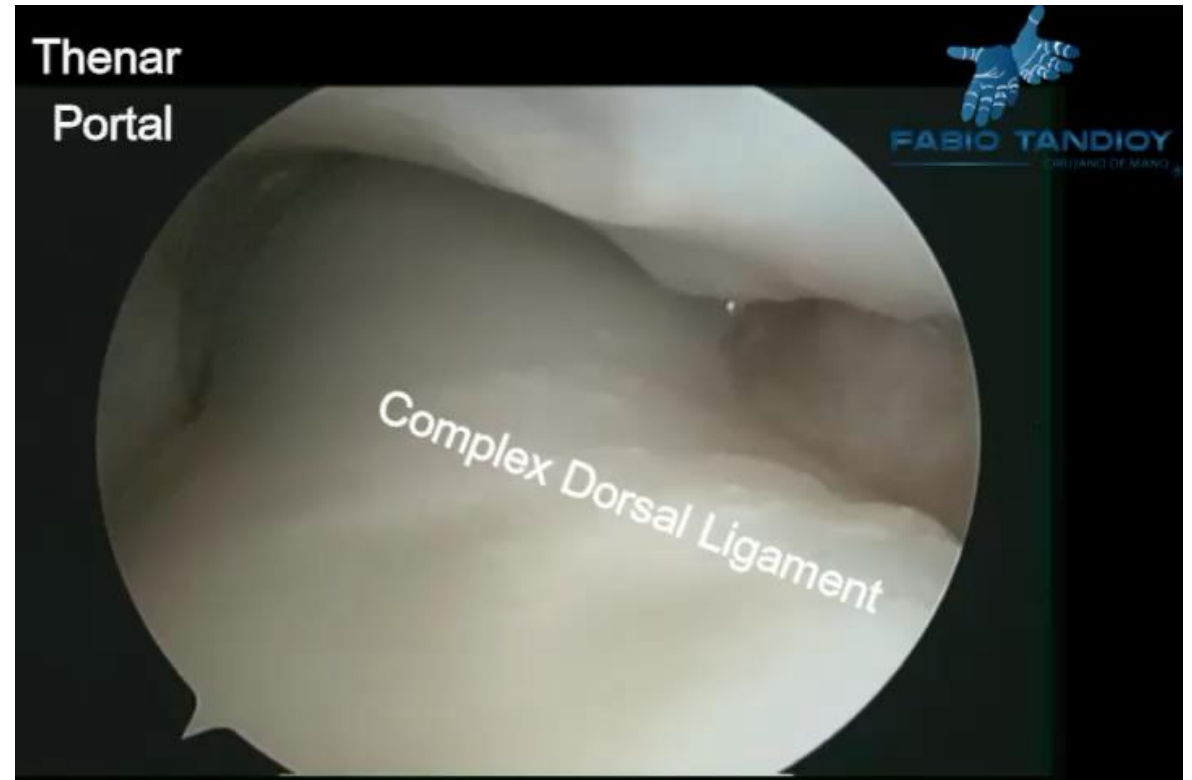
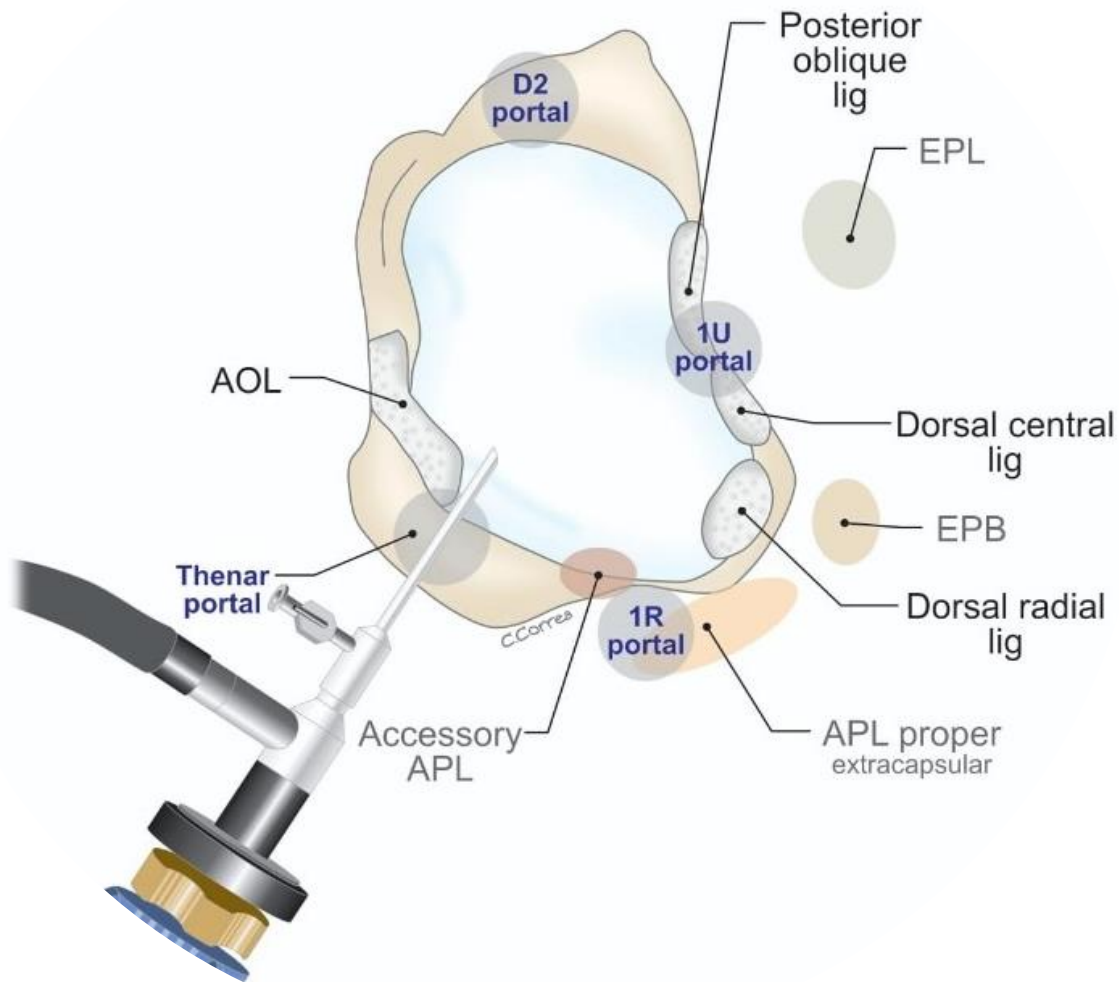
1U Portal



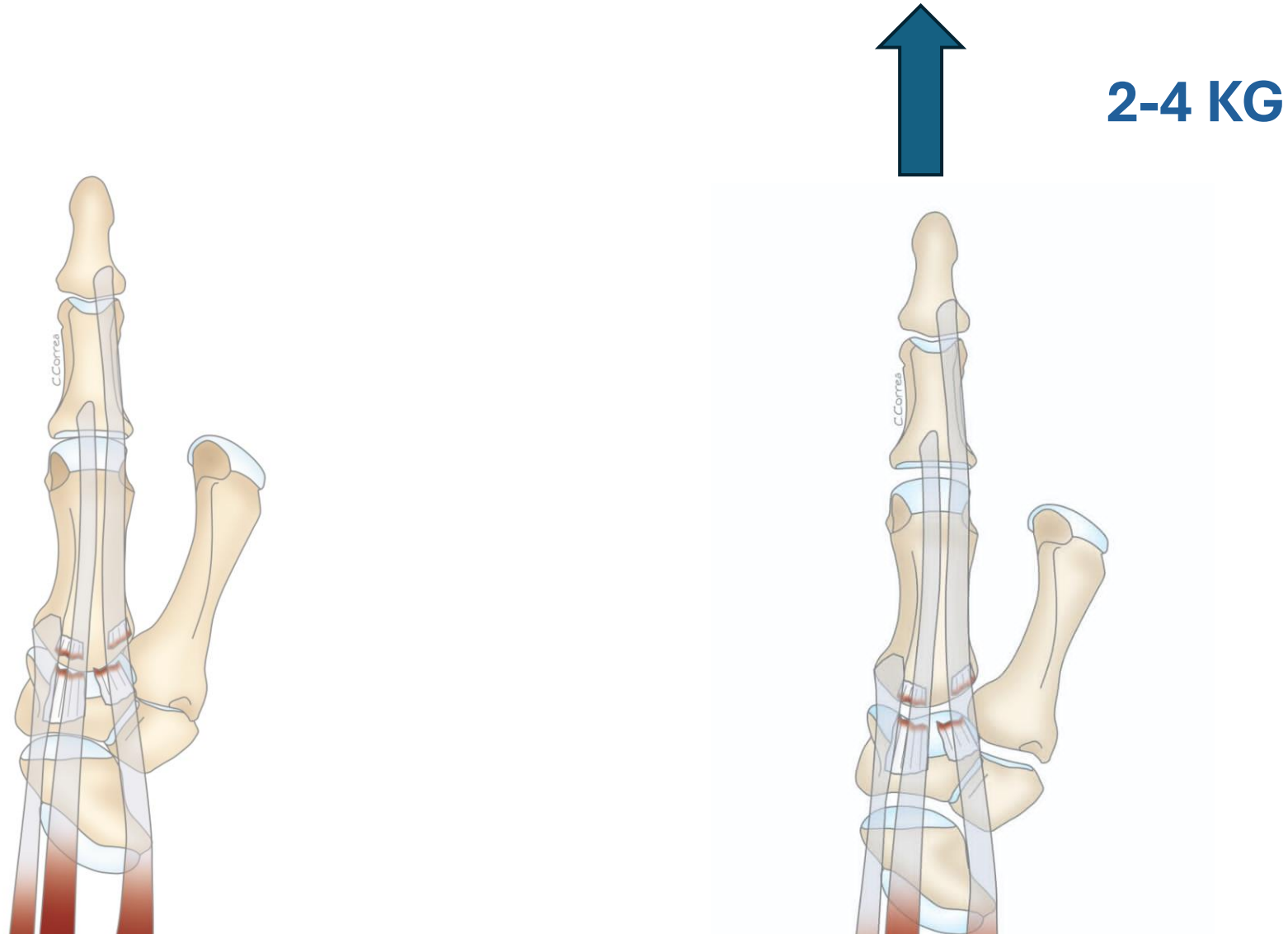
1R Portal



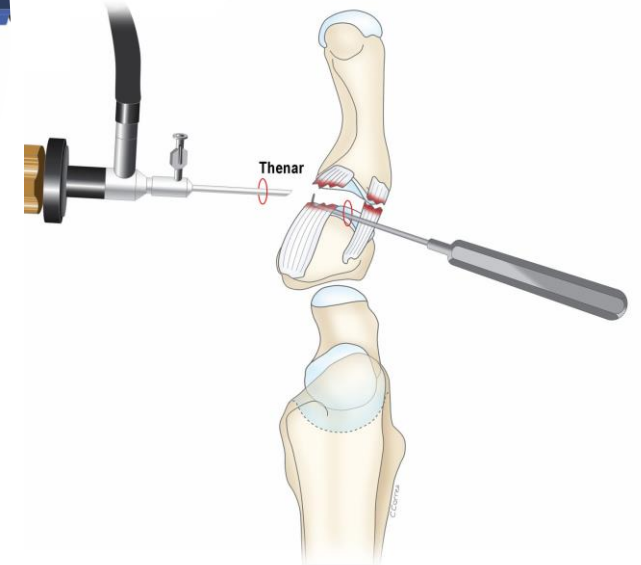
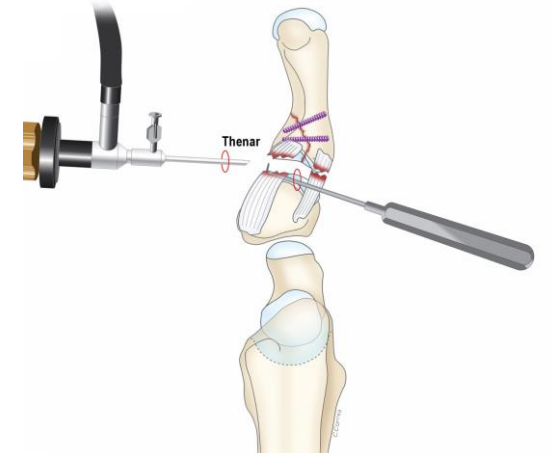
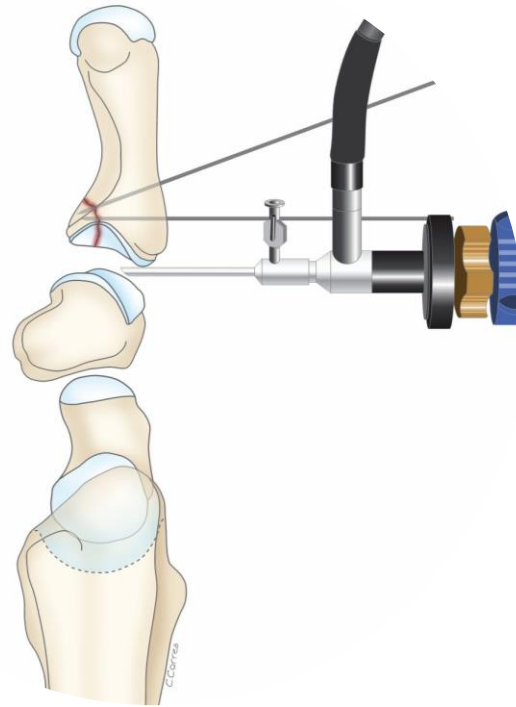
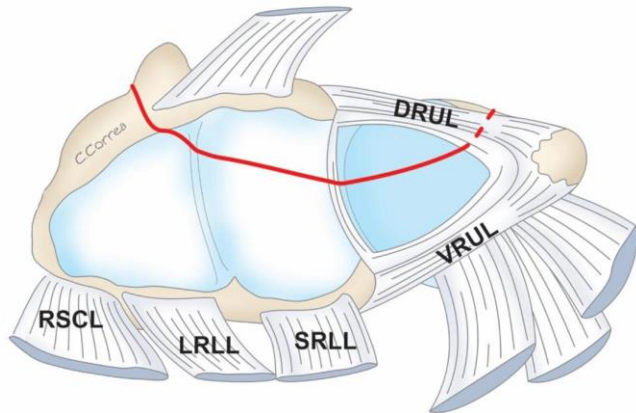
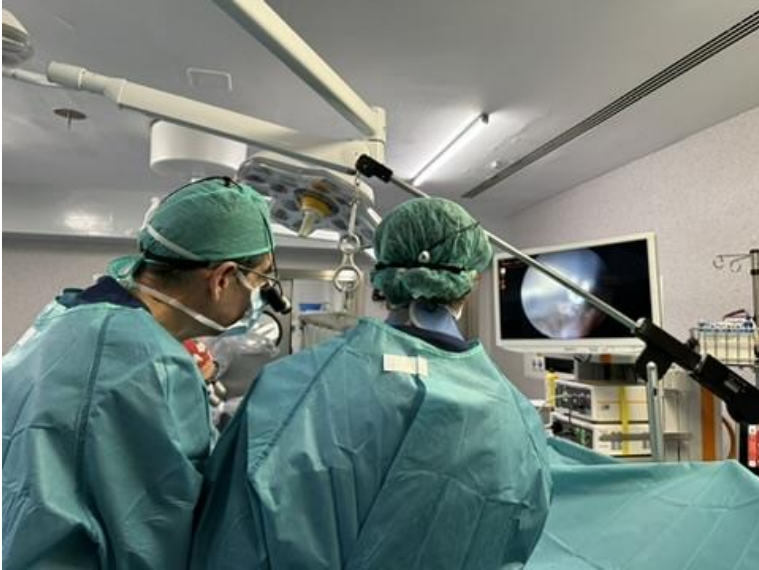Thenar Portal



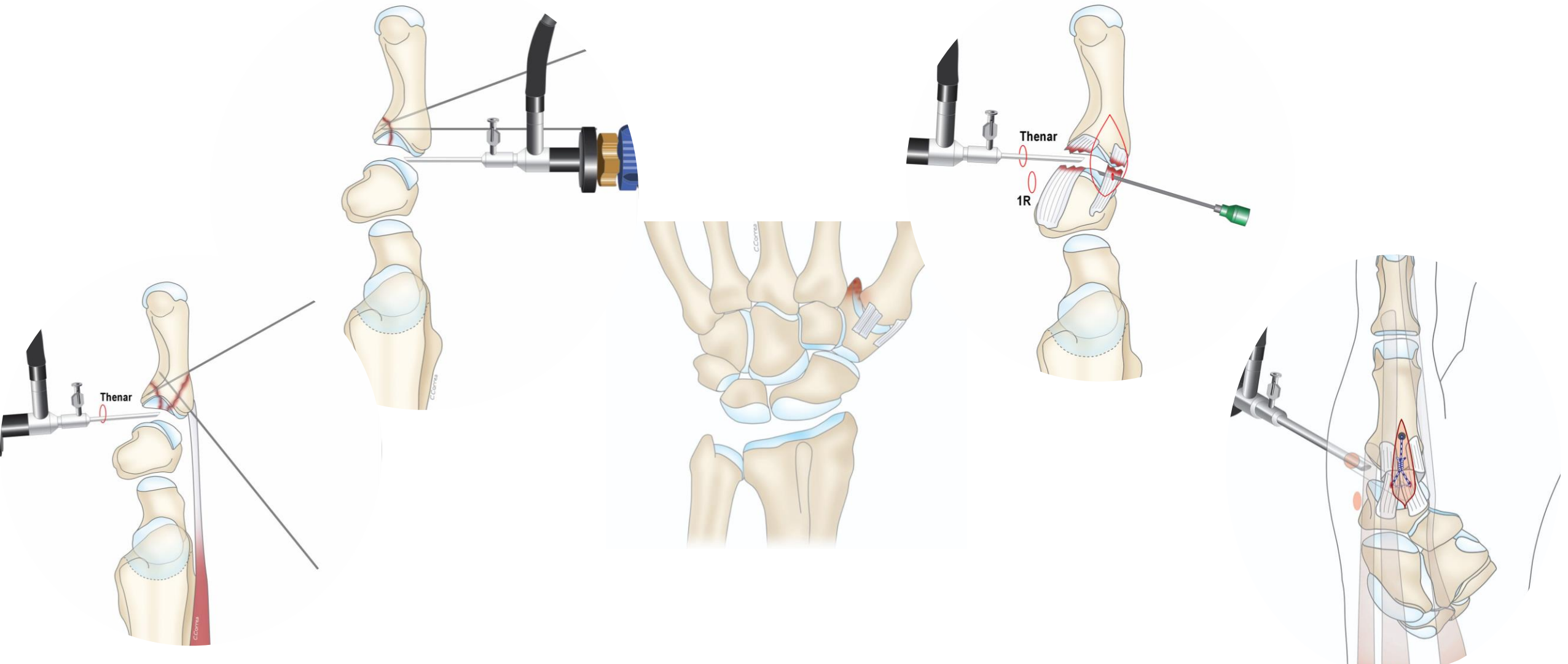
How much traction does the CMC-1 joint need?



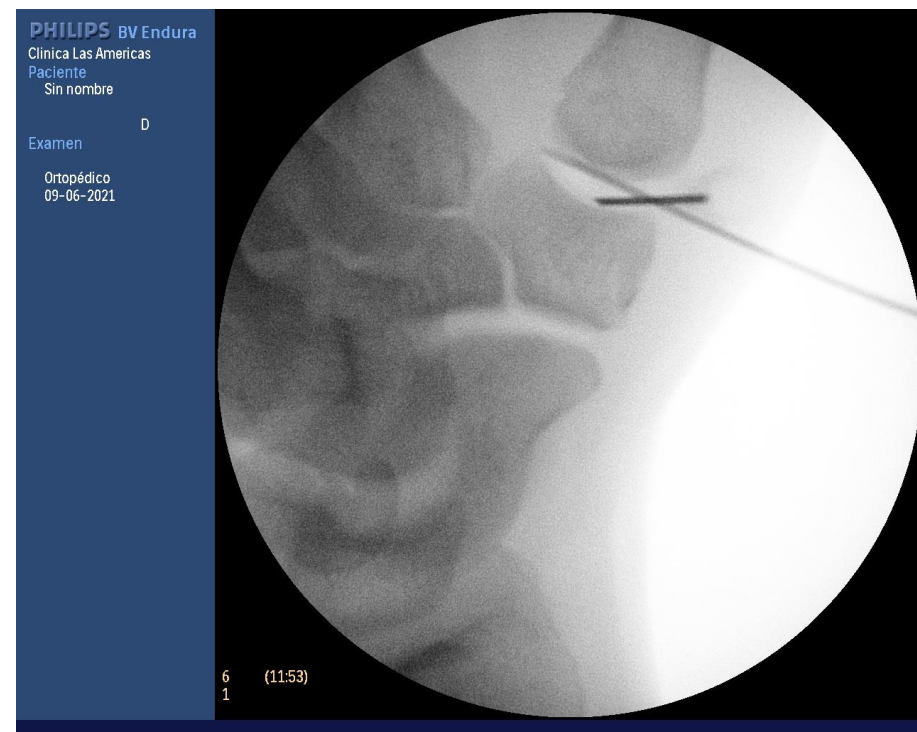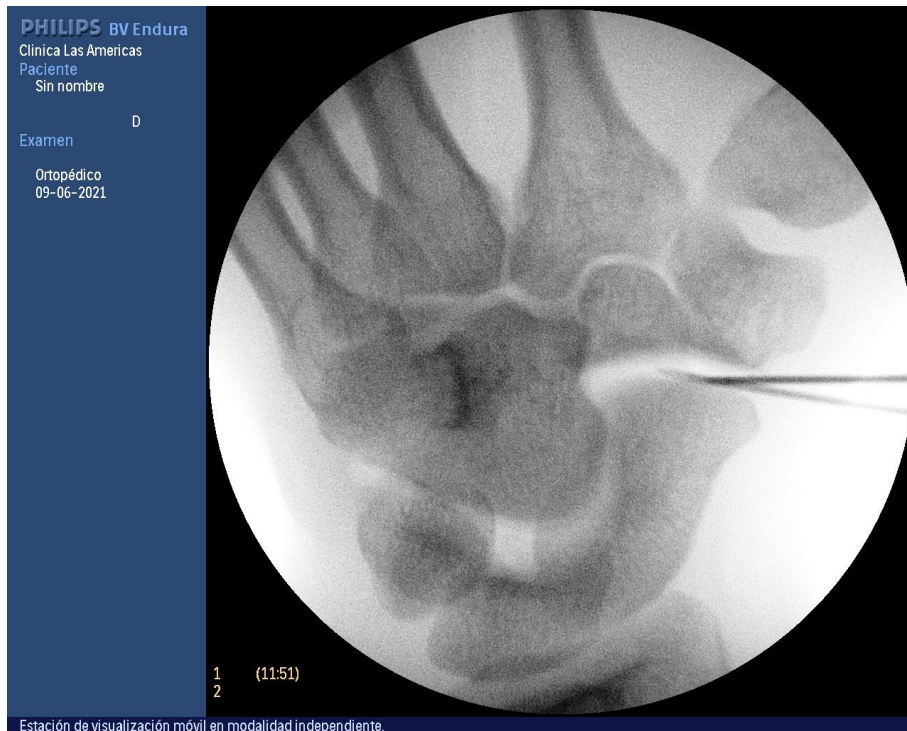
Indication for Arthroscopy in CMC 1 joint



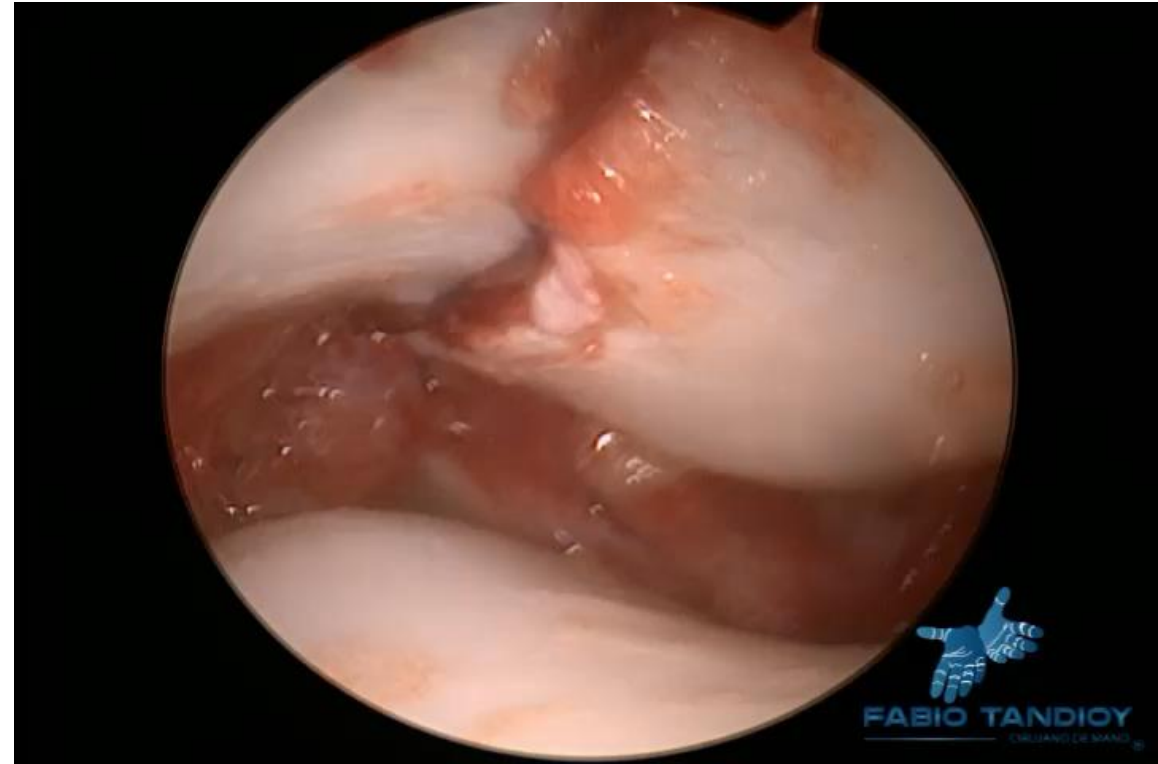
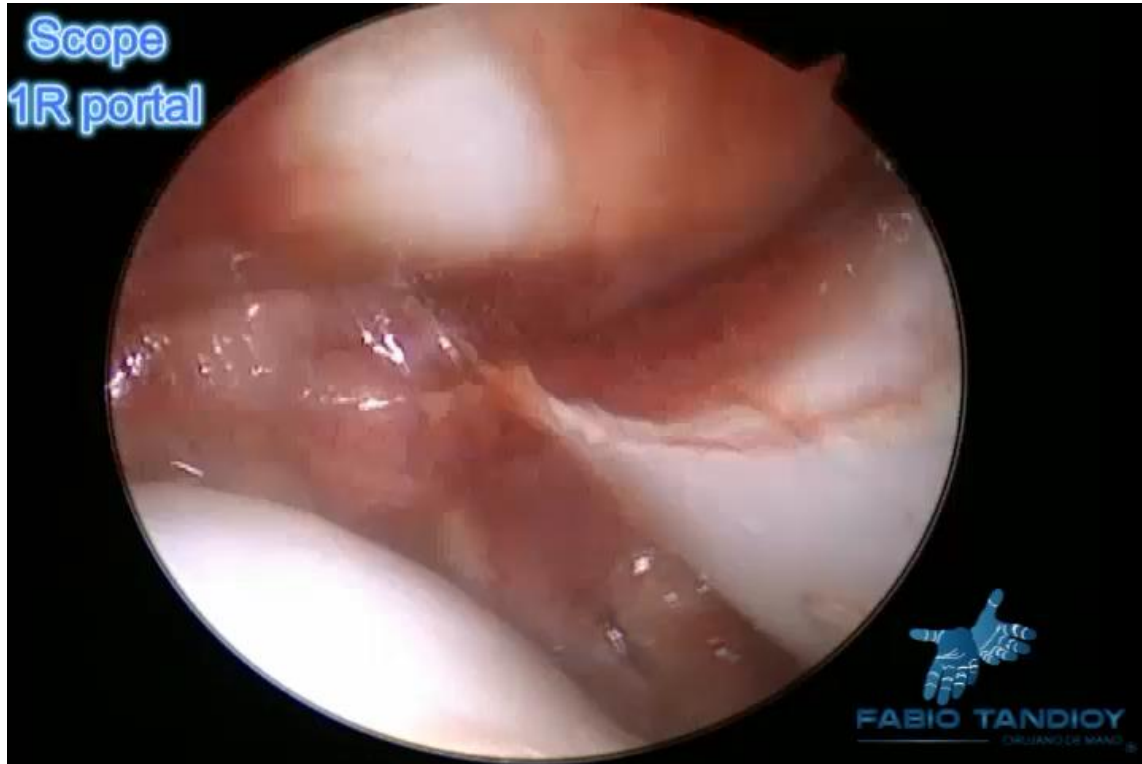Indication for Arthroscopy in CMC 1 joint



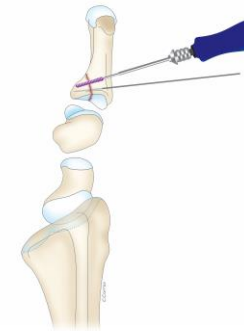
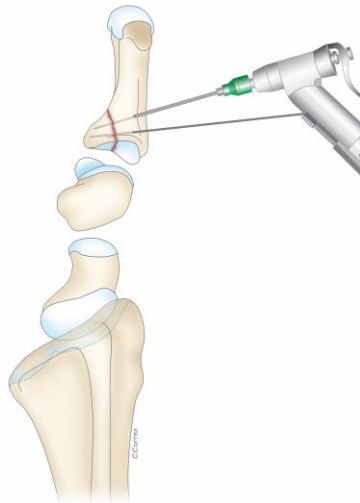
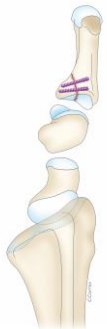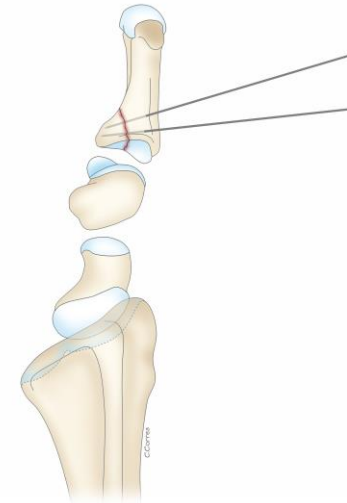
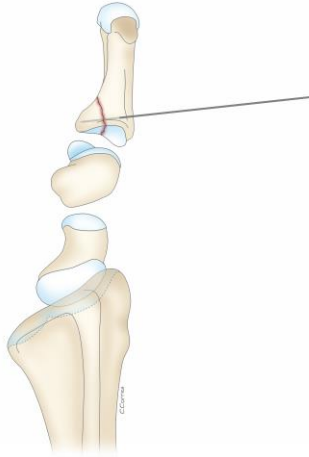
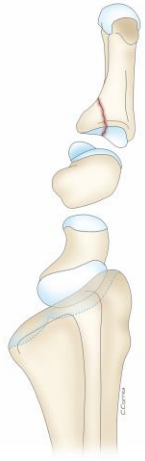
Bennet's Fracture



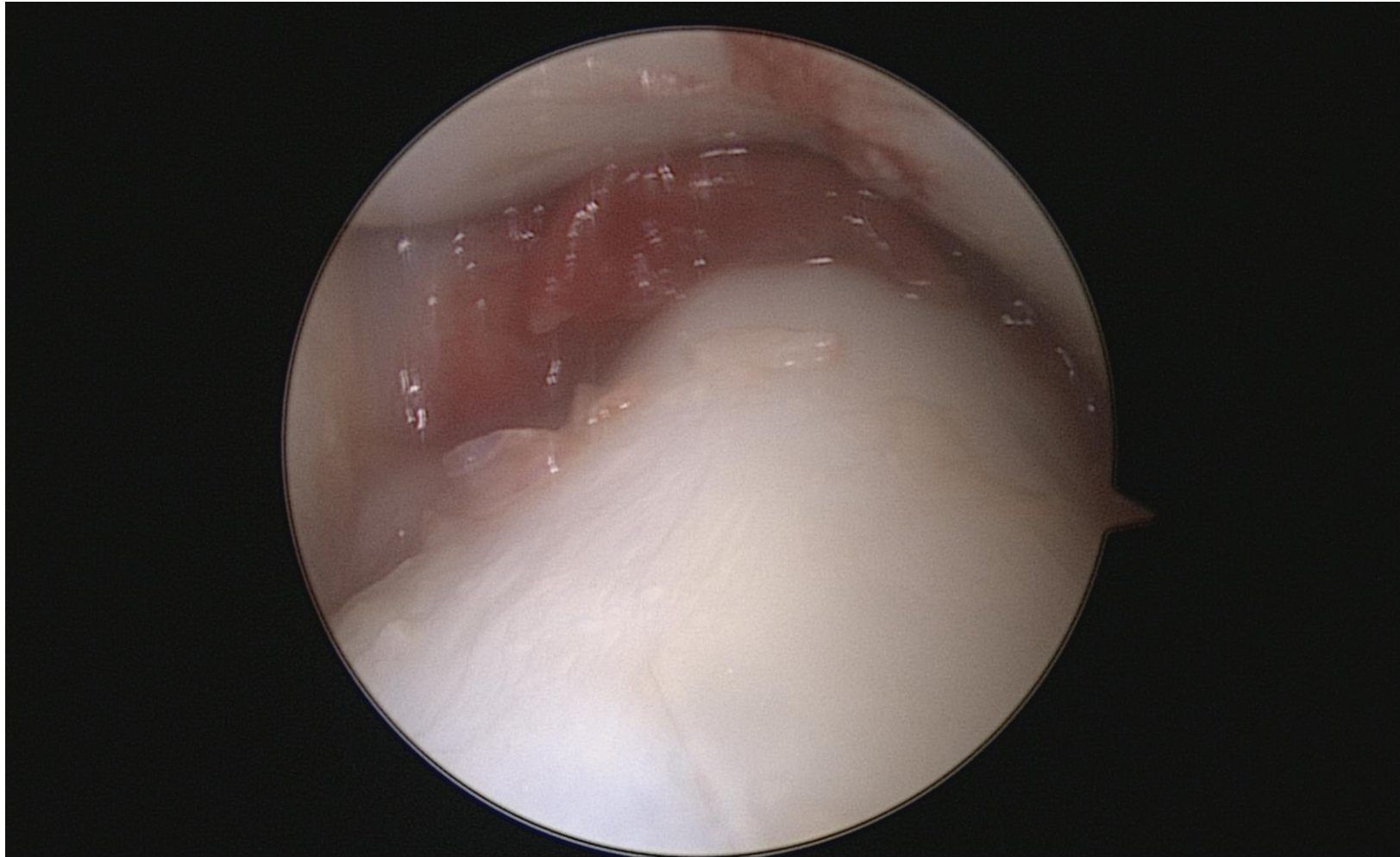
Bennet's Fracture



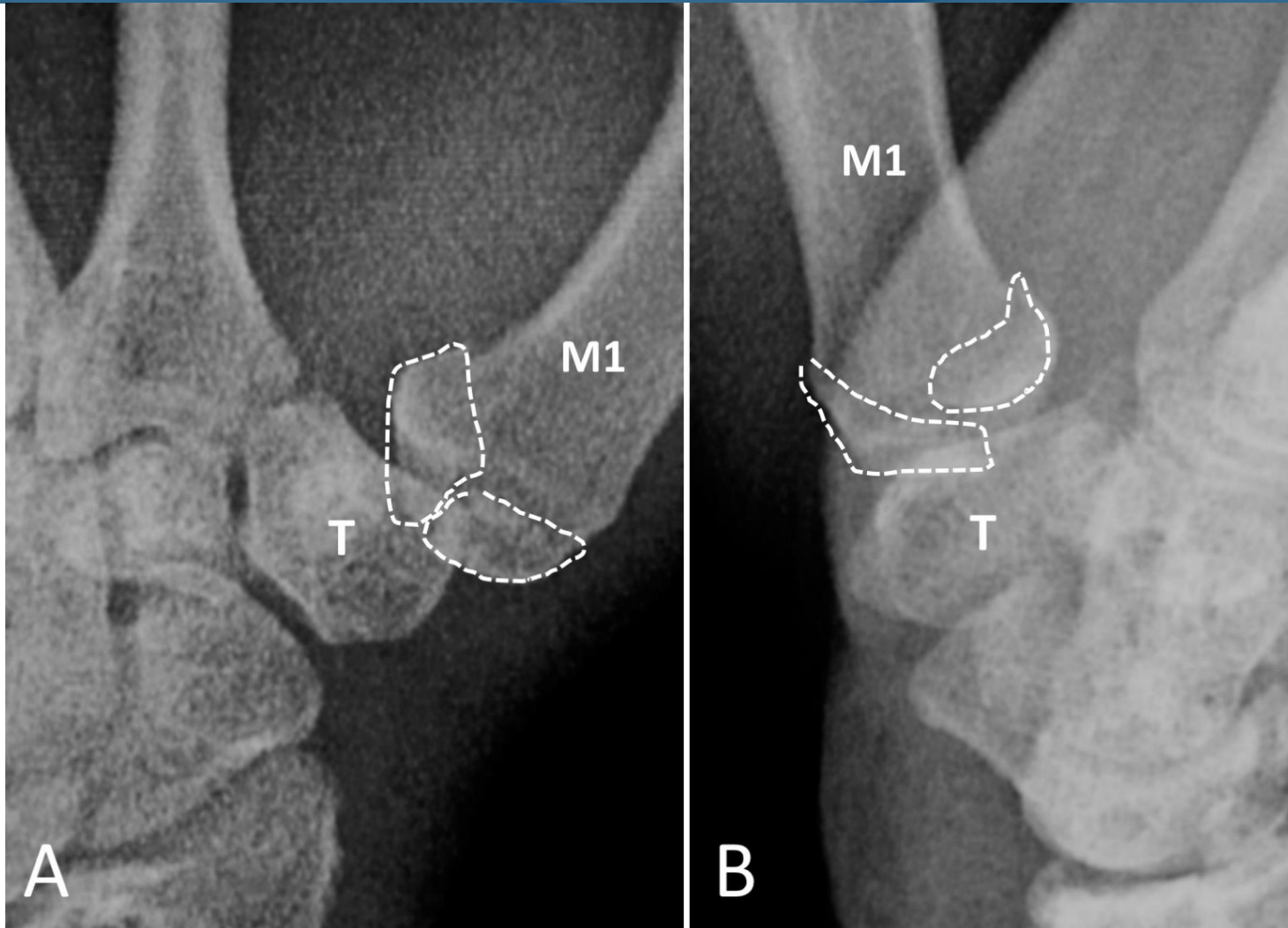
Bennet's Fracture



Bennet's Fracture

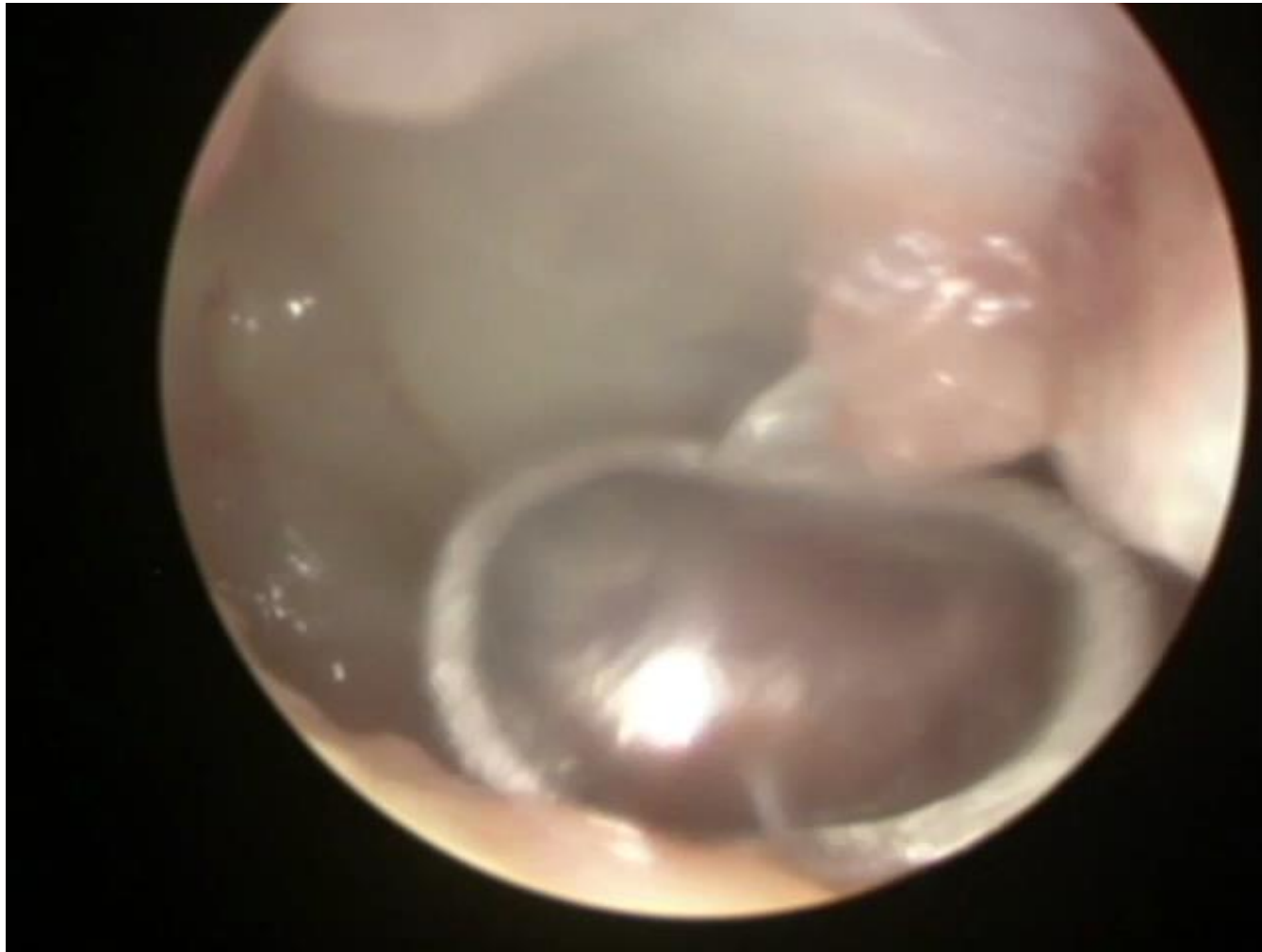


Rolando Fracture



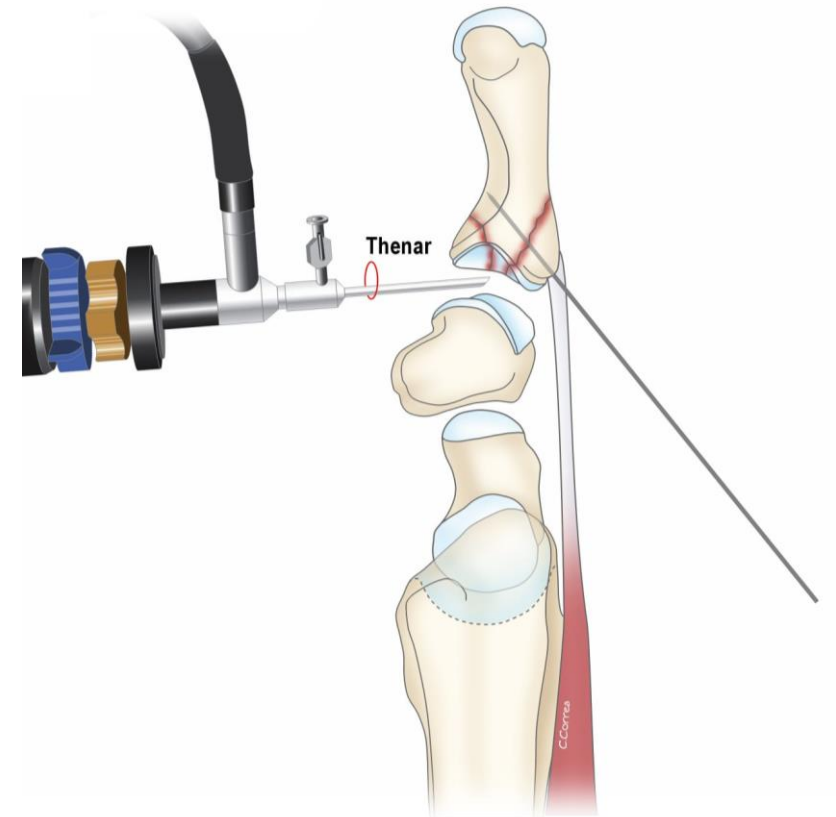
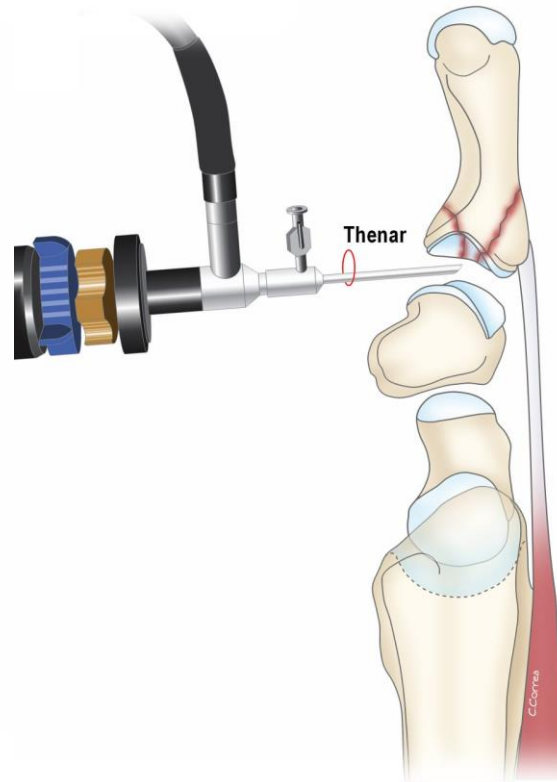
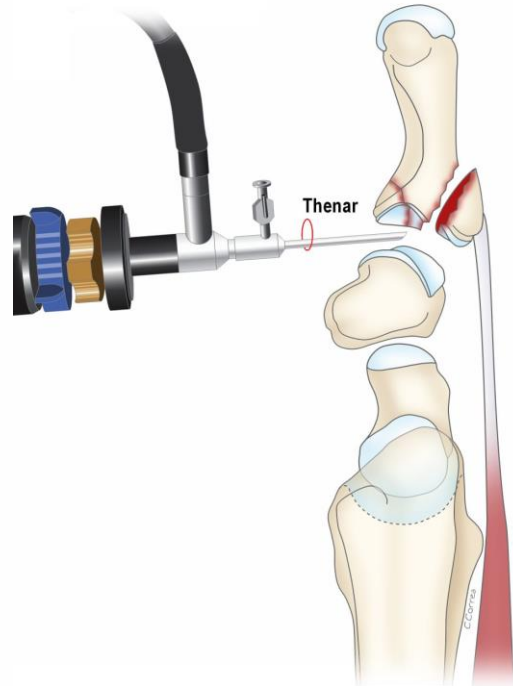
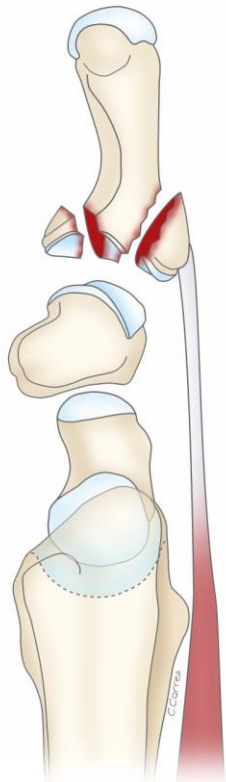
Courtesy
Lucian
Marcovici

Rolando Fracture

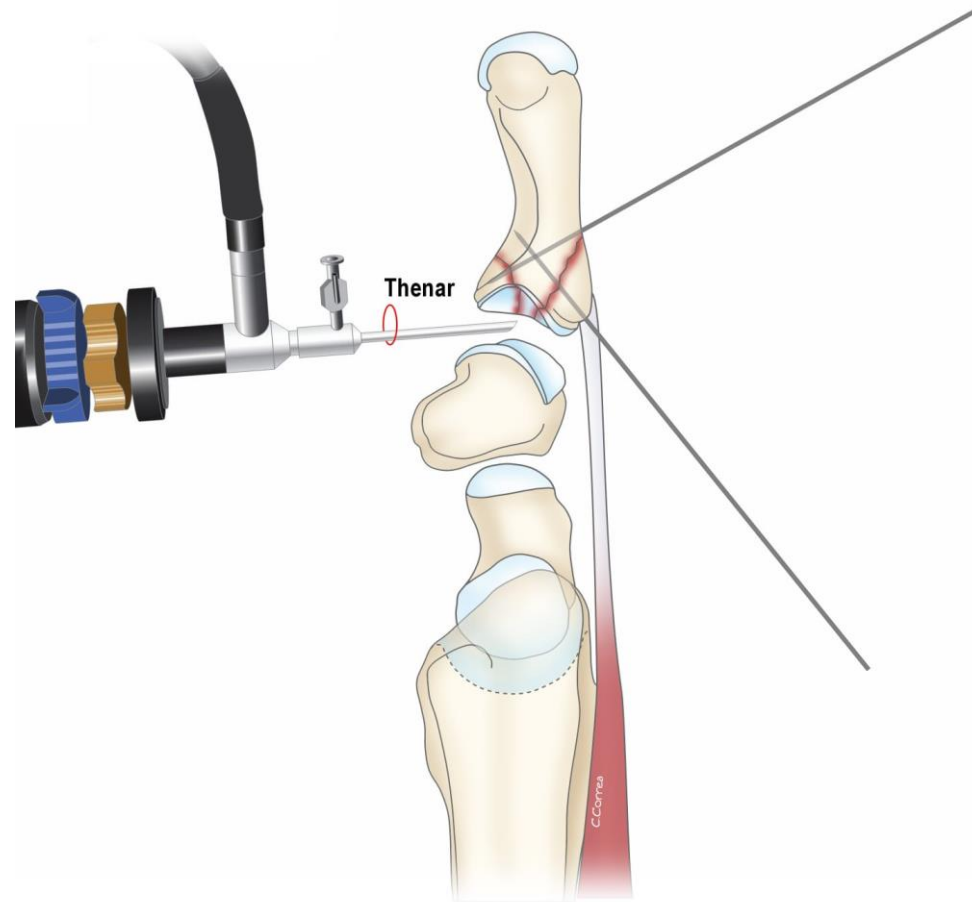


Courtesy
Lucian
Marcovici

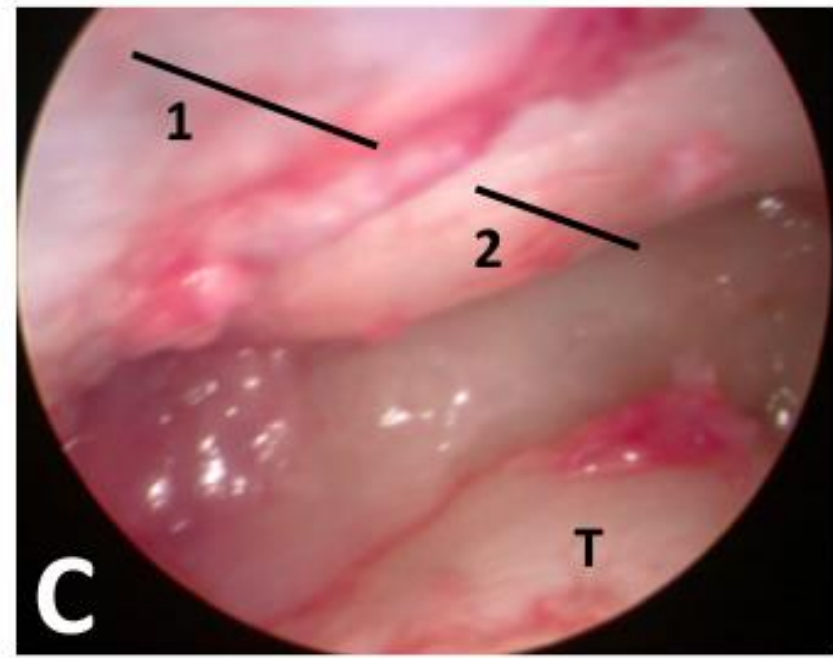
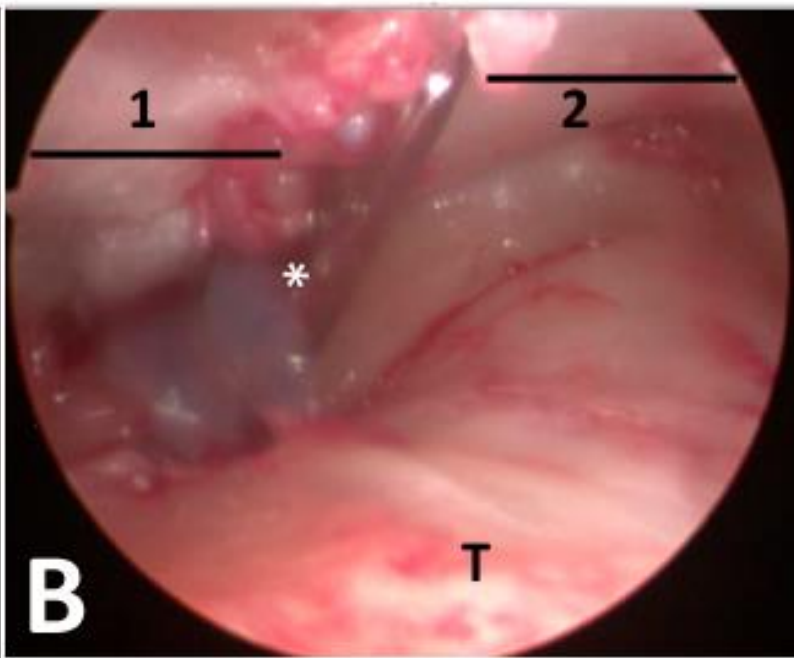
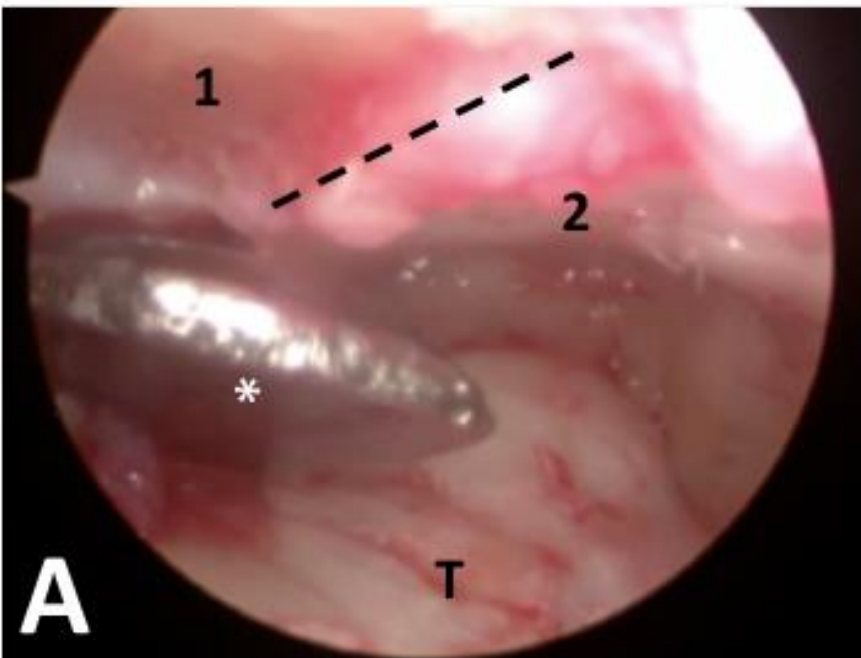Rolando Fracture



Rolando Fracture

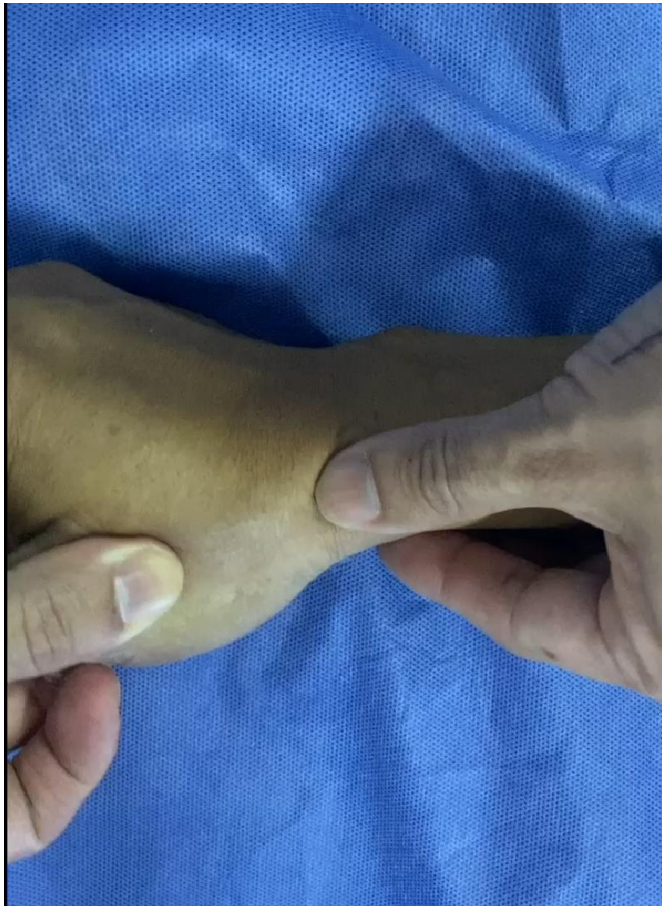

Rolando Fracture

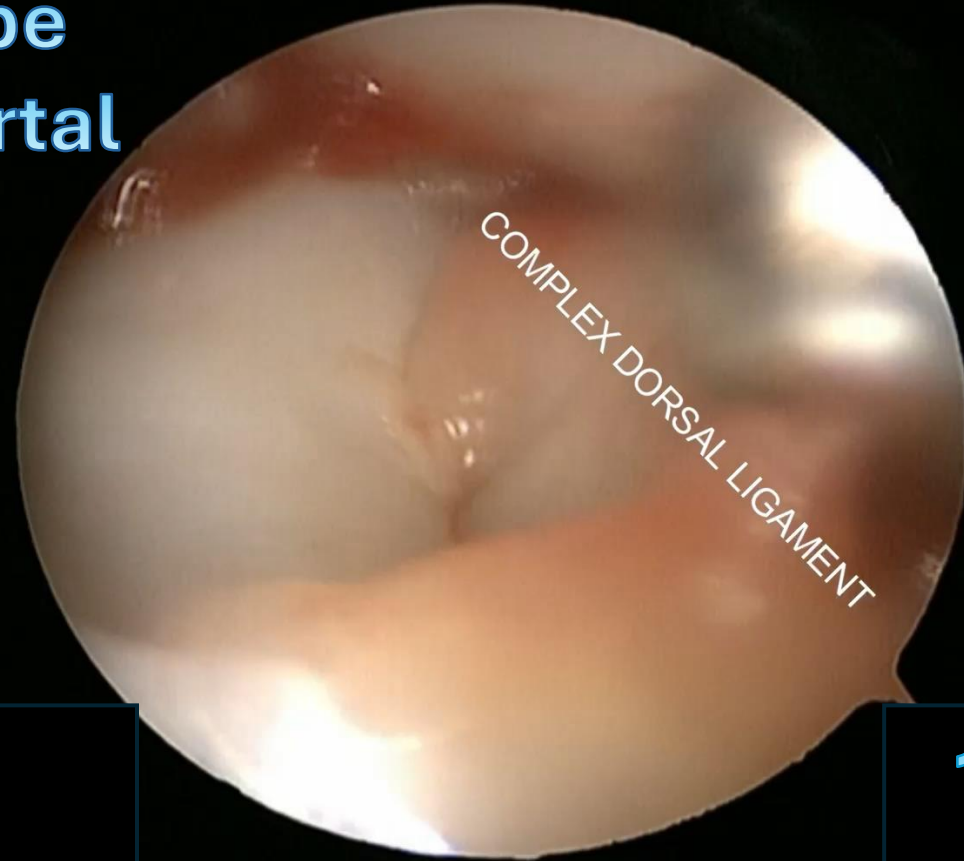


Courtesy
Lucian
Marcovici

Acute CMC 1 Joint dislocation

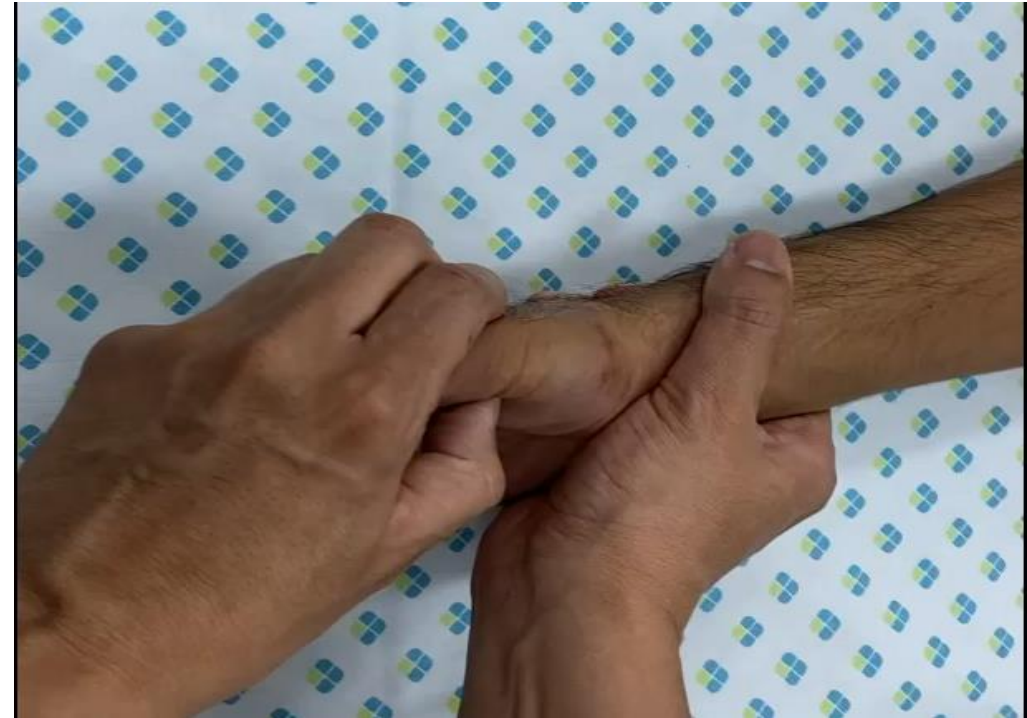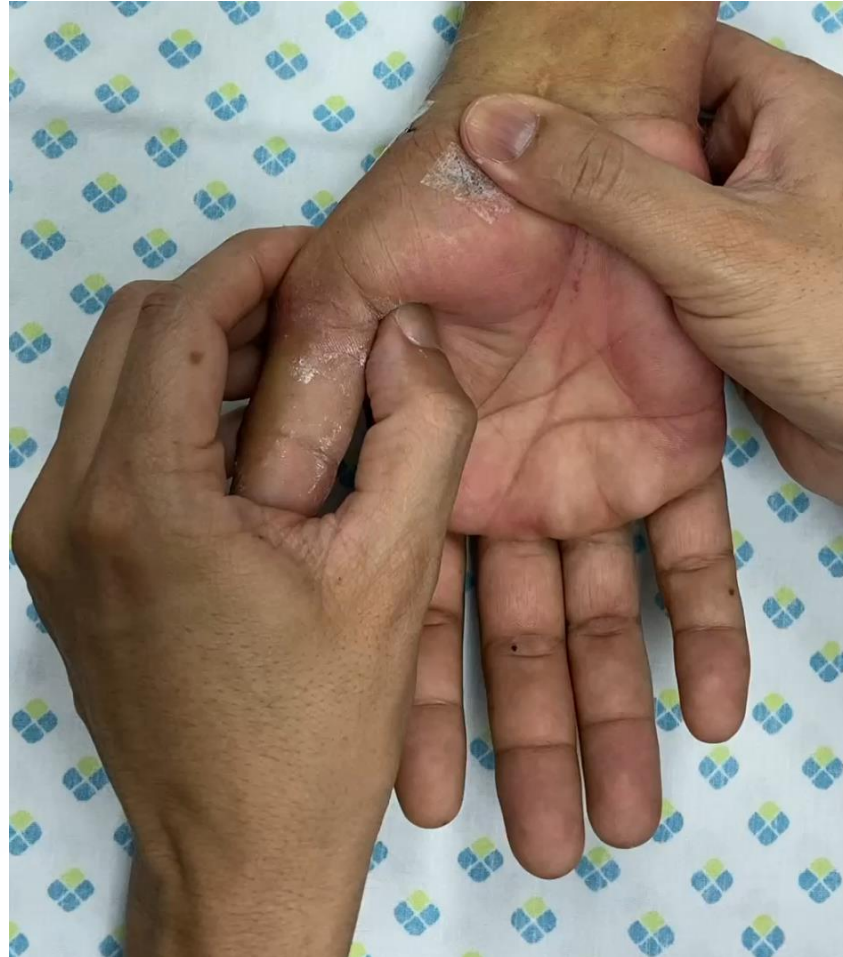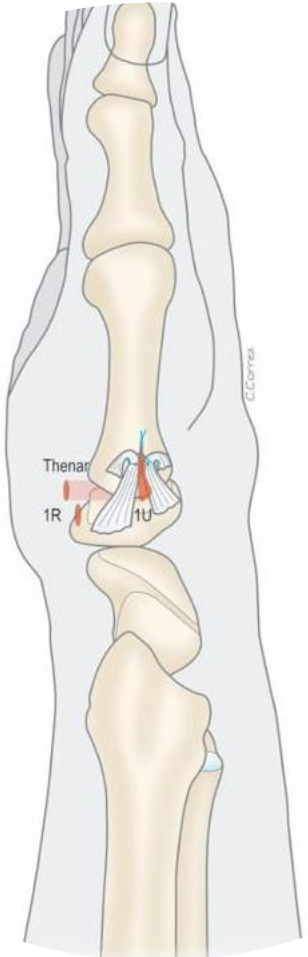


Scope
1R Portal

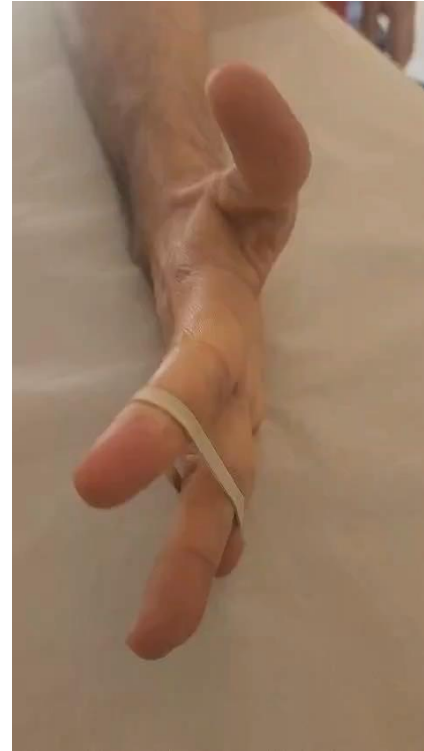
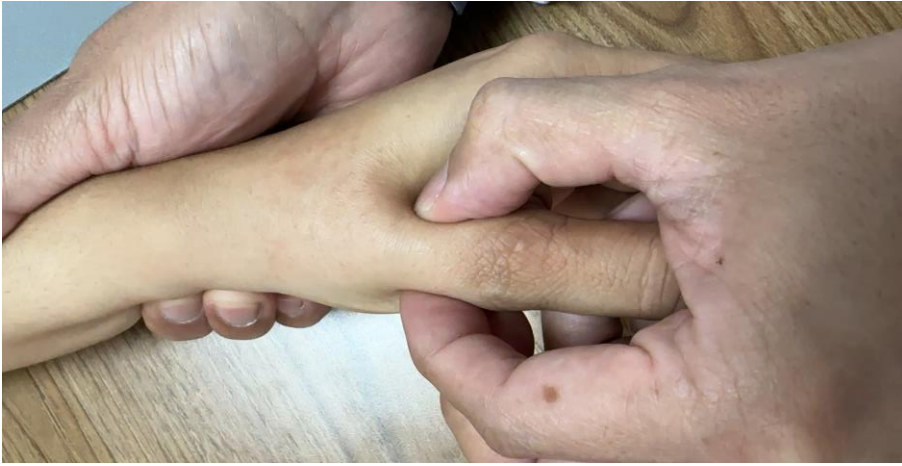
Hook
1u Portal

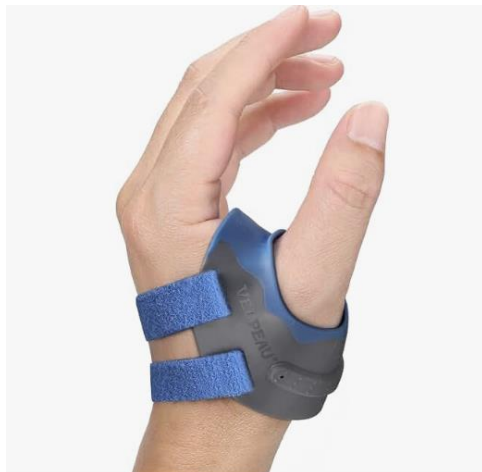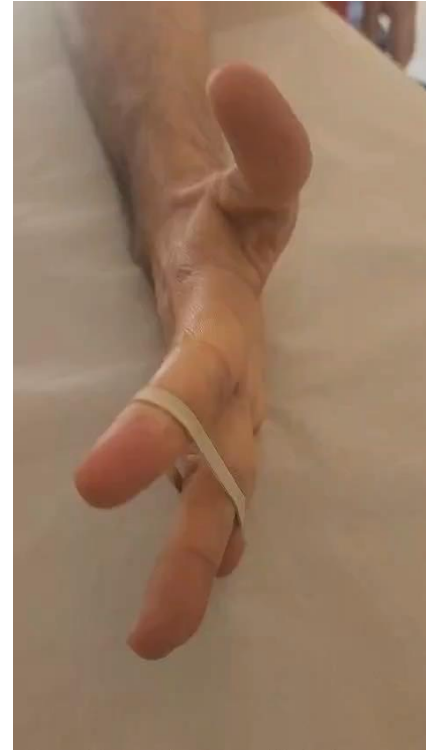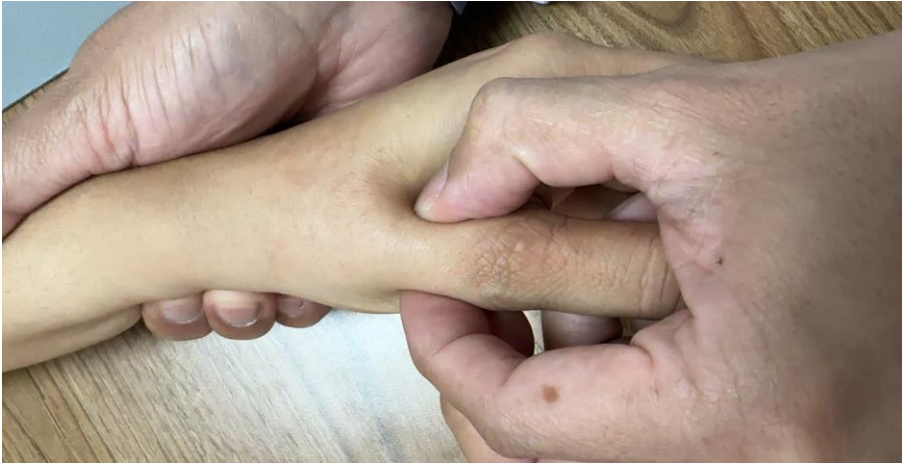Acute CMC 1 Joint dislocation



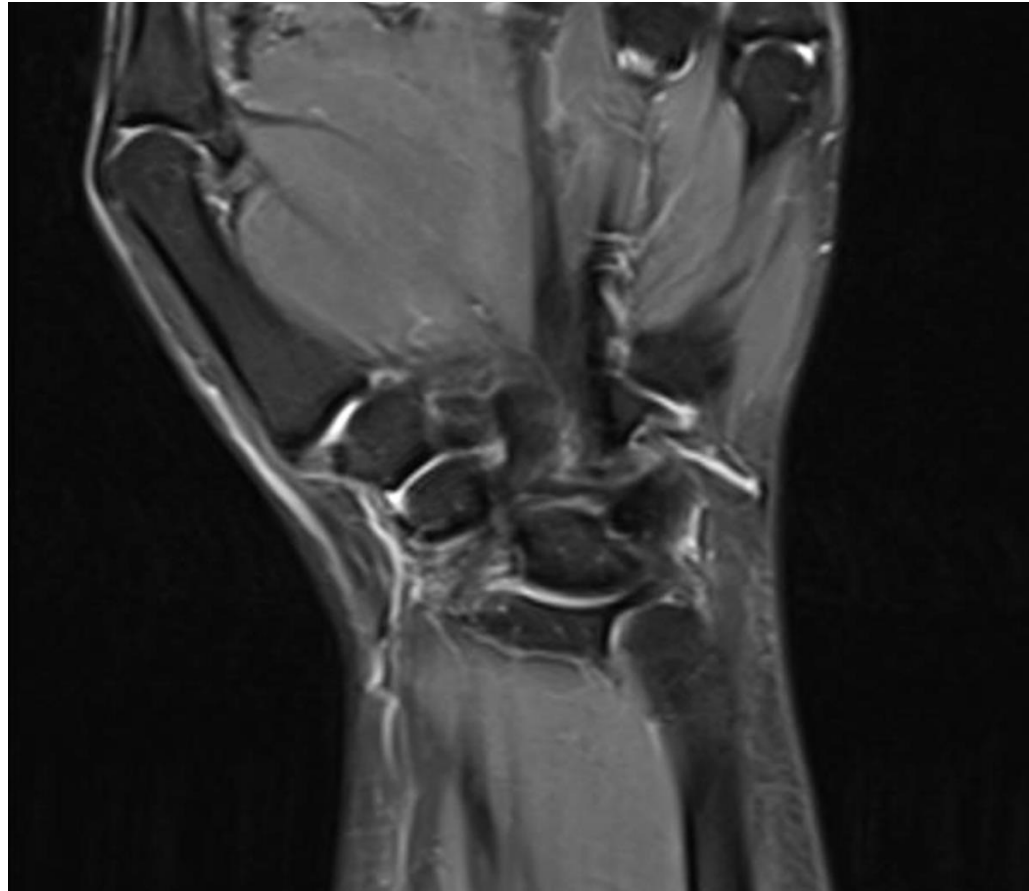
CMC 1 Joint Instability



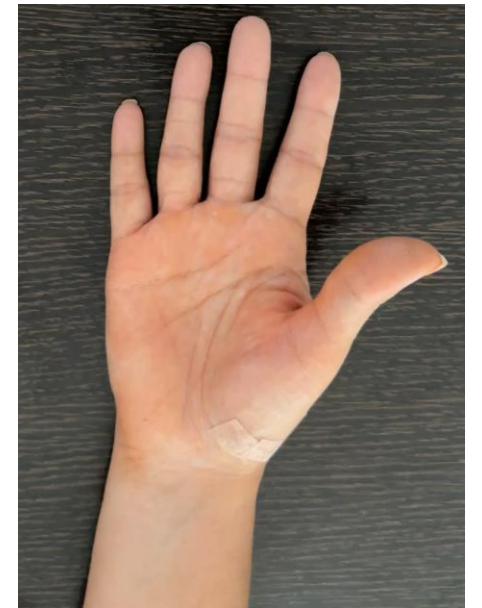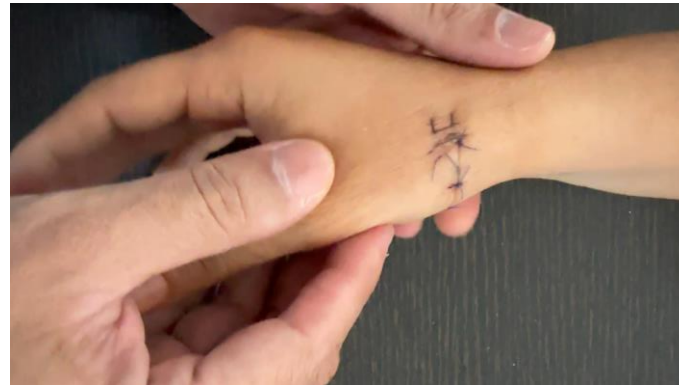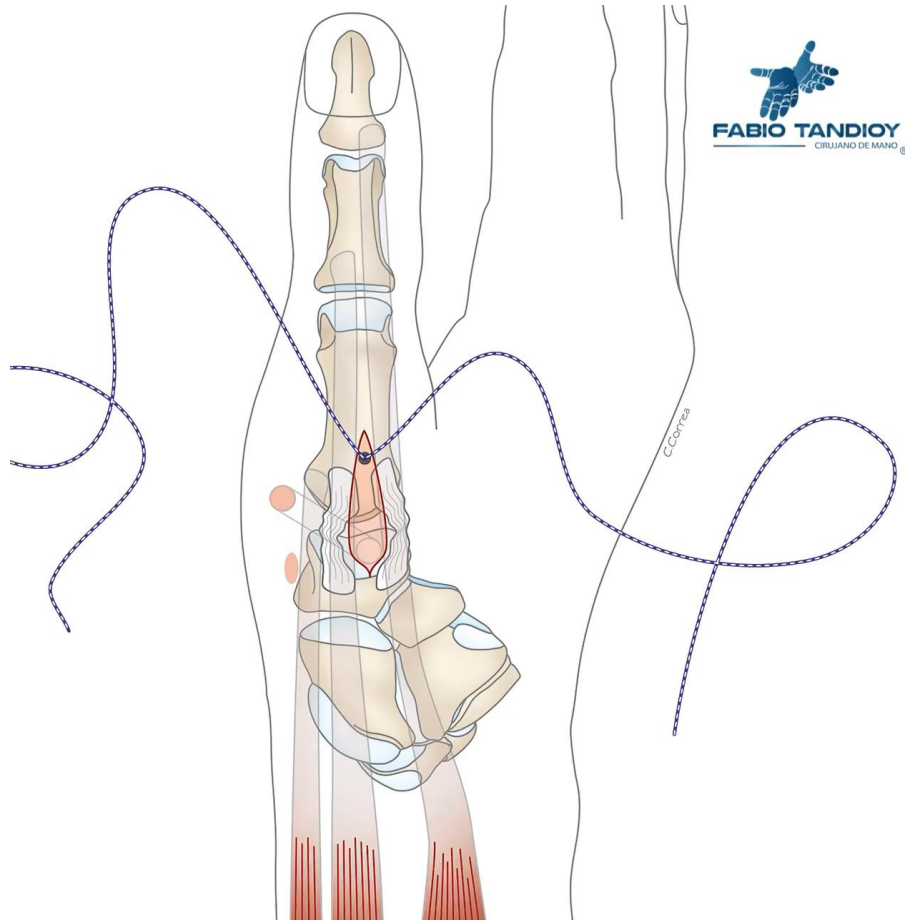
CMC 1 Joint Instability



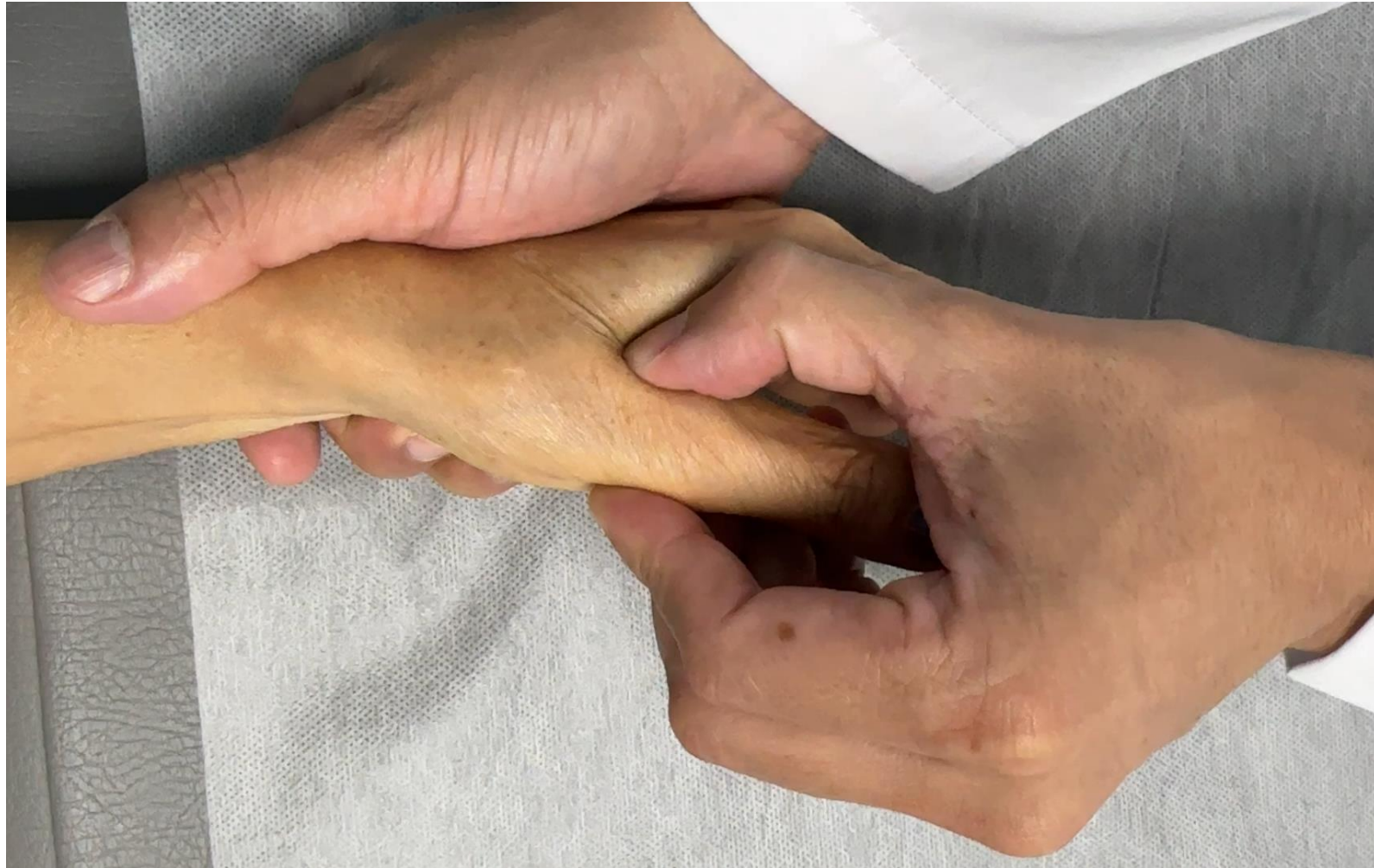CMC 1 Joint Instability



CMC 1 Joint Instability



CMC 1 Joint Instability





¡Gracias!



FABIO TANDIOY
CIRUJANO DE MANO



ASSH | American Society
for Surgery of the Hand